

FACEBOOK LIVE

In association
with

Society of Vascular Nurses



MIXED ULCERATION: WHAT YOU NEED TO KNOW



*BY LOUISE ALLEN AND
DR LEANNE ATKIN*

**THURSDAY 27TH AUGUST
7:30PM**

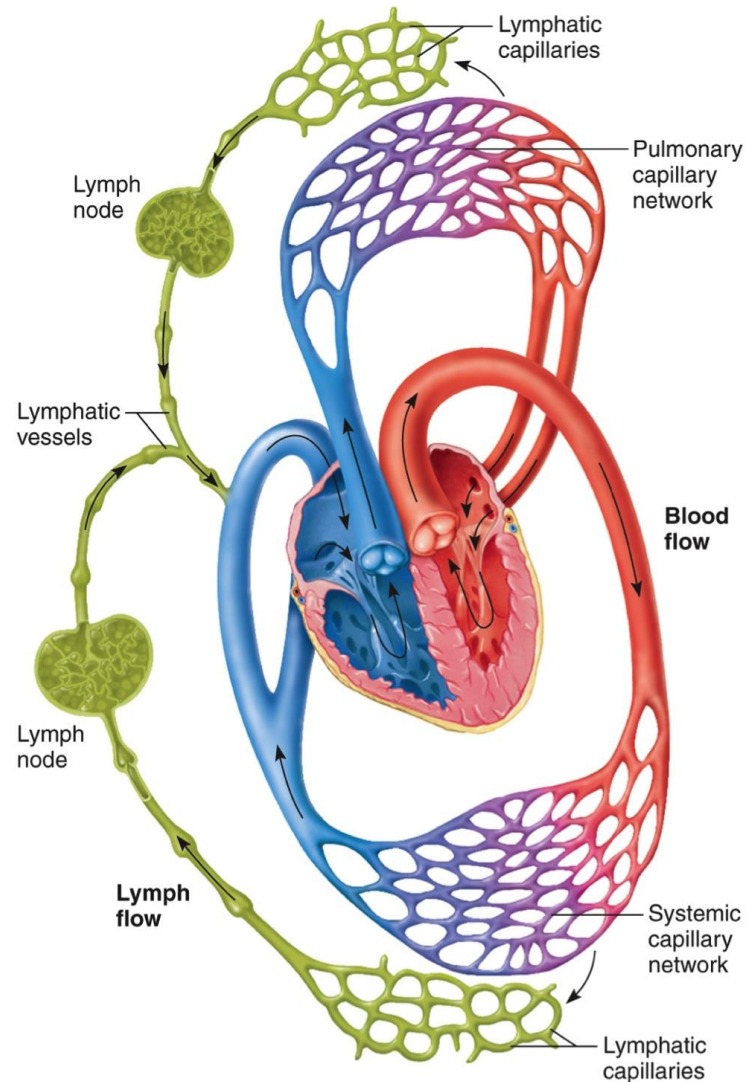
Mixed Ulceration: what you need to know

Miss Louise Allen

Introduction

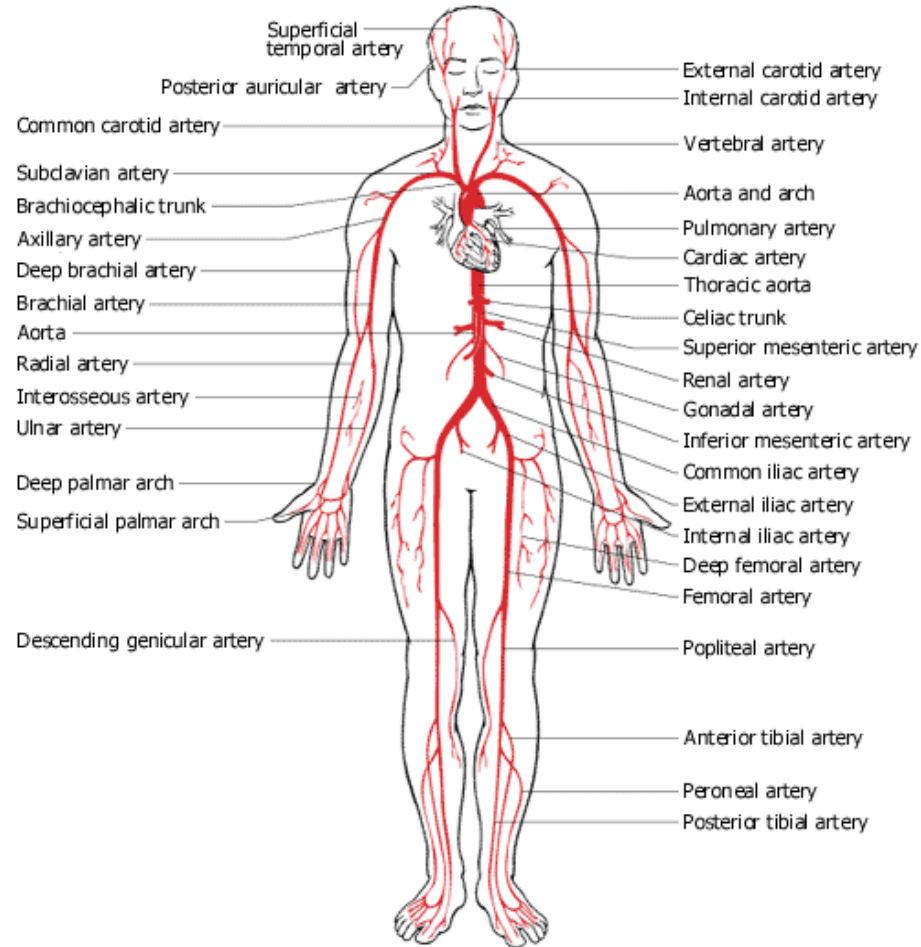
- 1. Mixed ulceration: what does this really mean?**
- 2. Anatomy and physiology of the venous and arterial system**
- 3. Pathophysiology of the venous and arterial system**
- 4. How to identify venous and arterial ulcers**
- 5. How to manage mixed ulcerations**
- 6. Why early intervention is crucial**

Anatomy and physiology



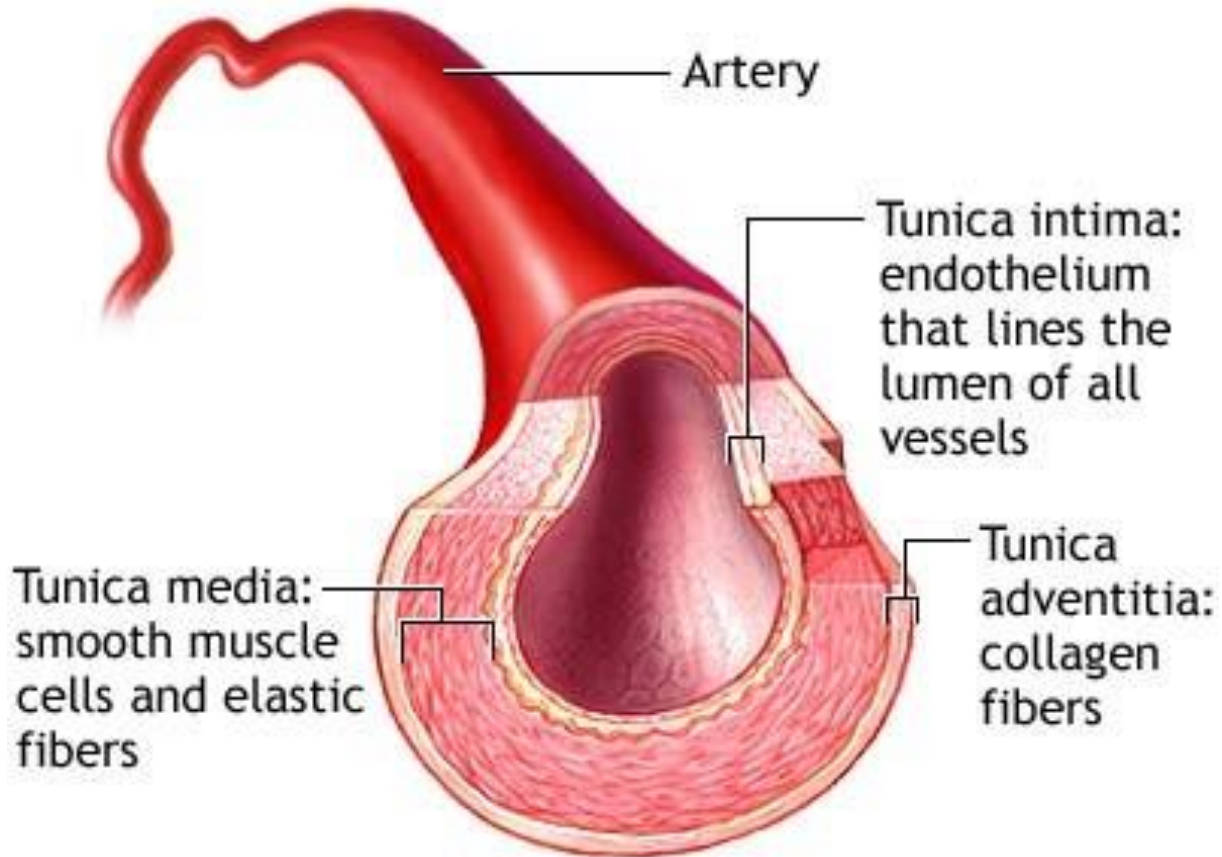
- **Circulatory system**
- **Arterial system**
 - Artery
 - Arterioles
- **Capillaries**
- **Venous system**
 - Venules
 - Vein
- **Lymphatic system**

Anatomy and physiology



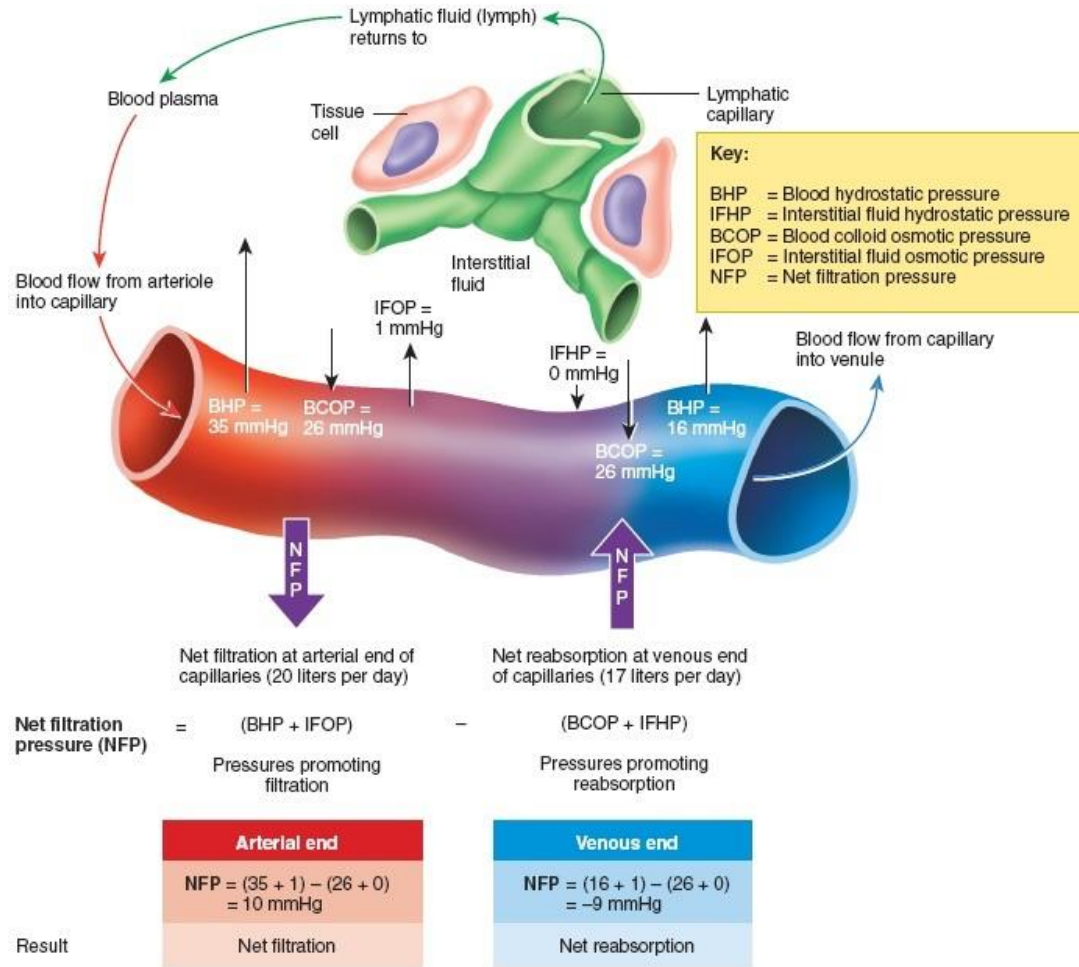
- **Arterial system**
- **Function**
 - Deliver oxygen
 - Deliver nutrients

Anatomy and physiology



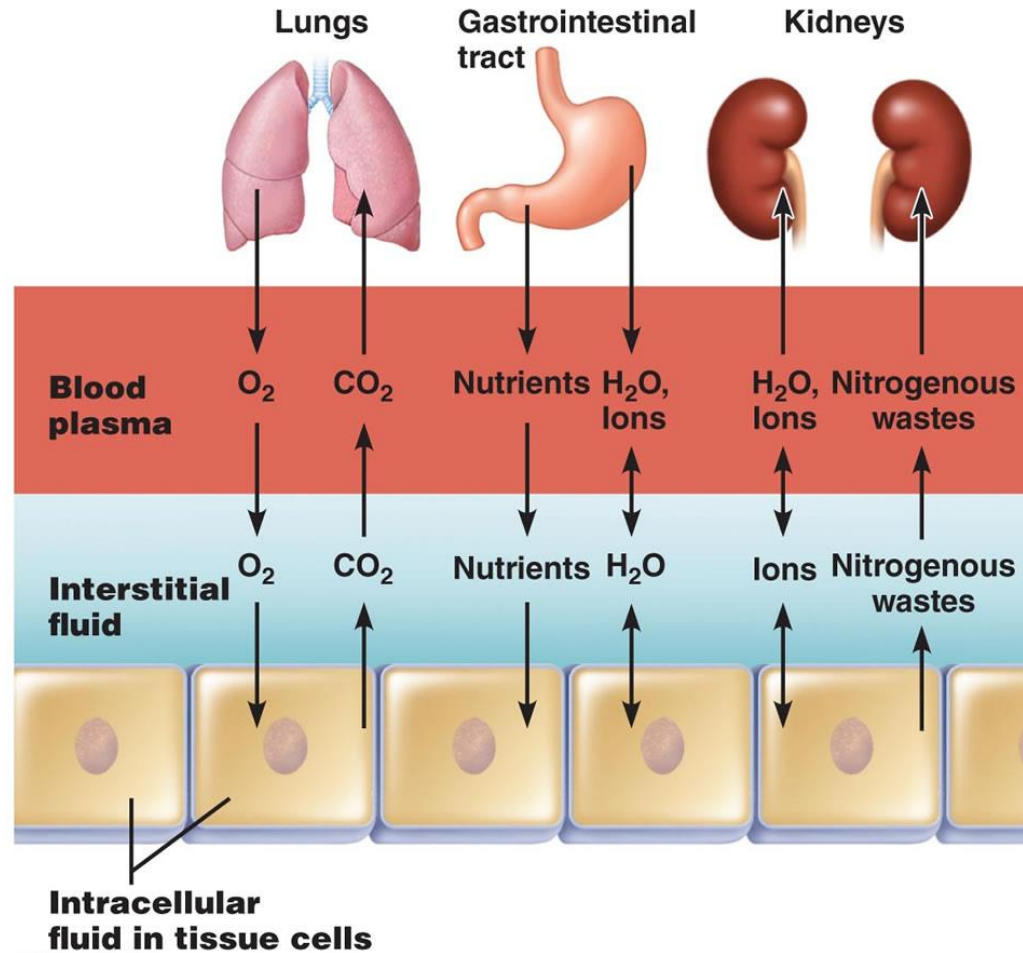
- Artery structure
- Three layers
- Function of each layer
- Media changes

Anatomy and physiology



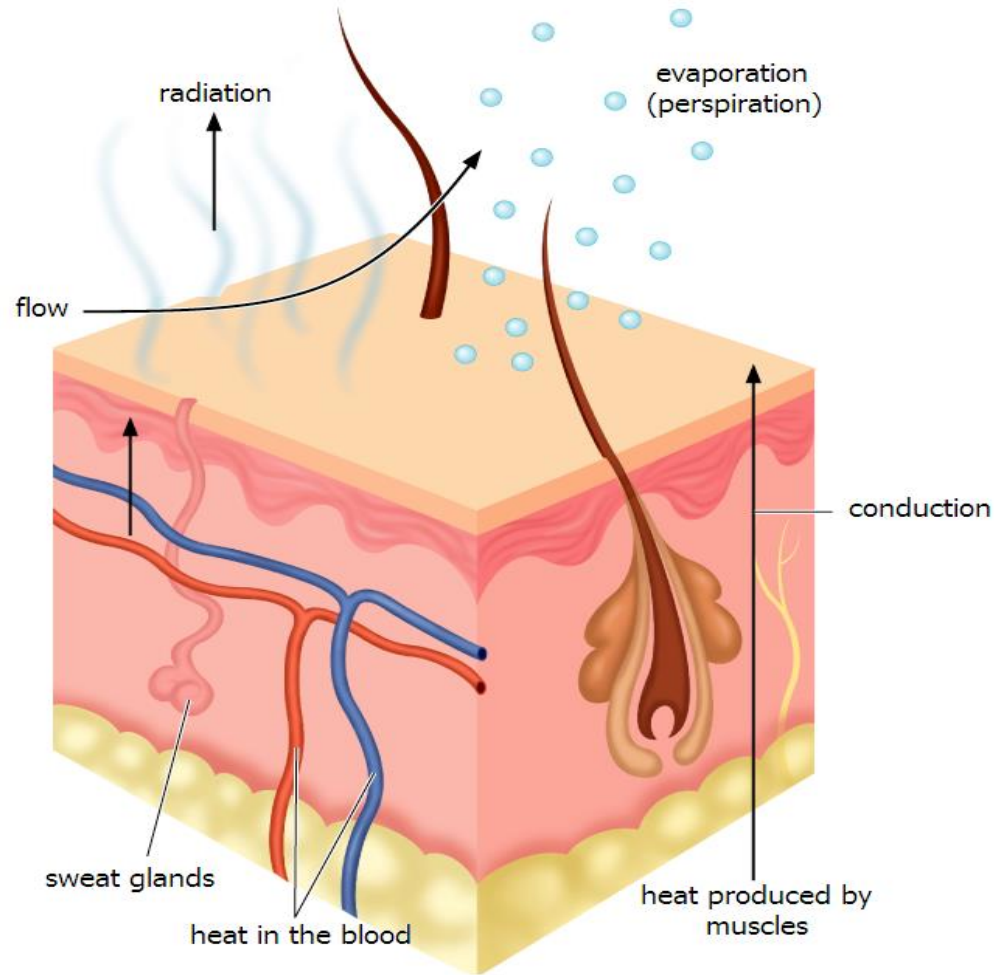
- **Capillaries**
- **Function**
 - Exchange of oxygen
 - Exchange of nutrients
- **Pressure related**
- **Proteins remain**
- **20 L fluid**

Anatomy and physiology



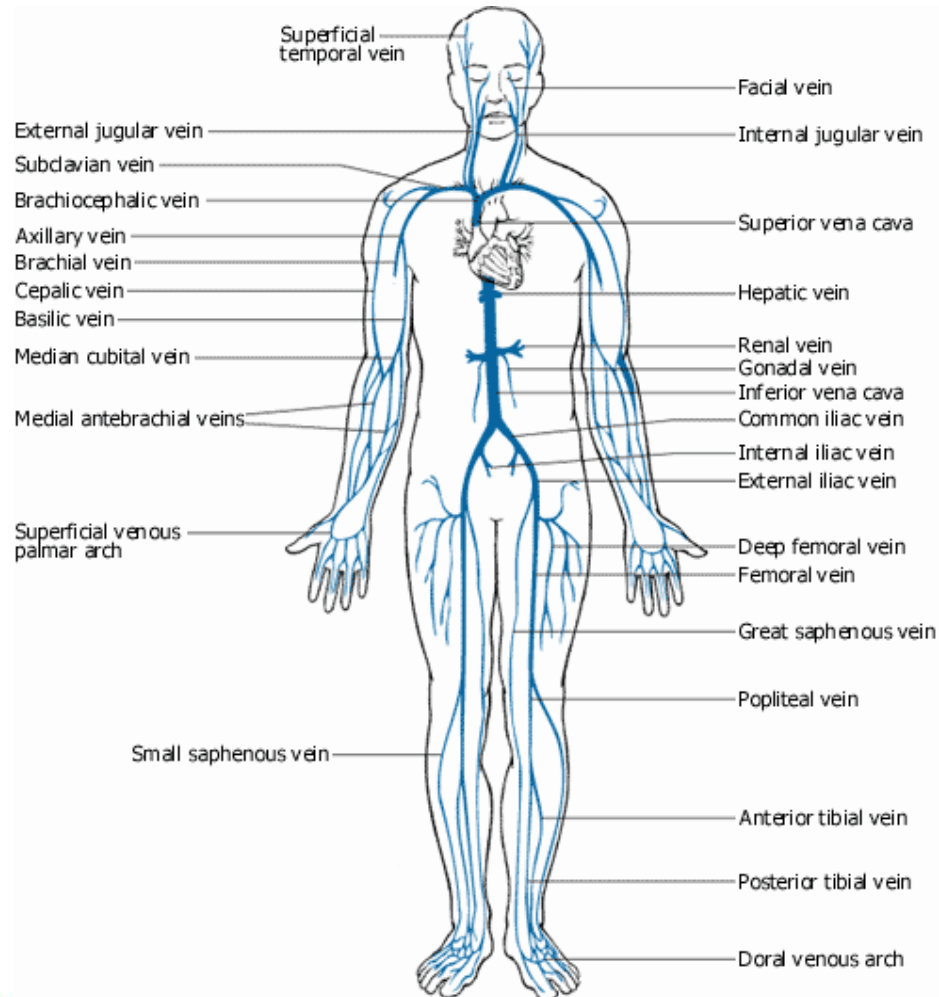
- **Capillaries**
- **Function**
 - Exchange of oxygen
 - Exchange of nutrients
- **Pressure related**
- **Proteins remain**
- **20 L fluid**

Anatomy and physiology



- **Capillaries**
- **Function**
 - Exchange of oxygen
 - Exchange of nutrients
 - Sweat glands
 - Hair follicles
 - Temperature control

Anatomy and physiology

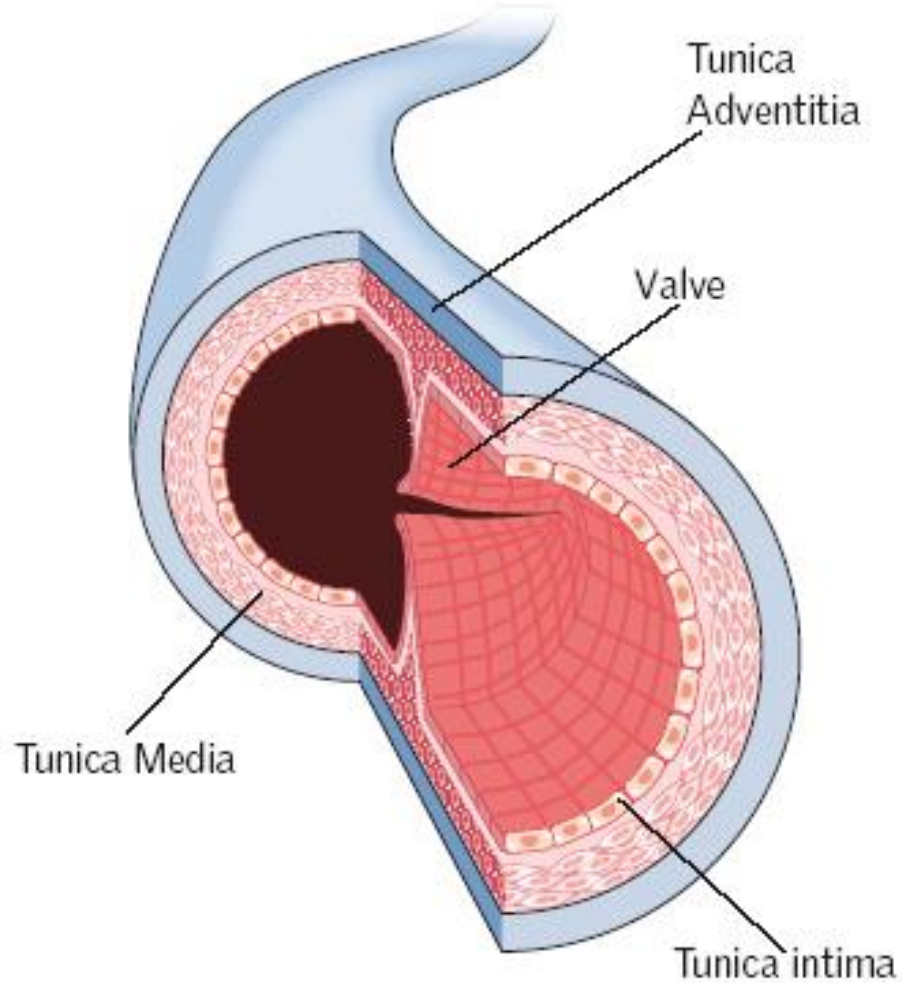


- **Venous system**

- **Function**

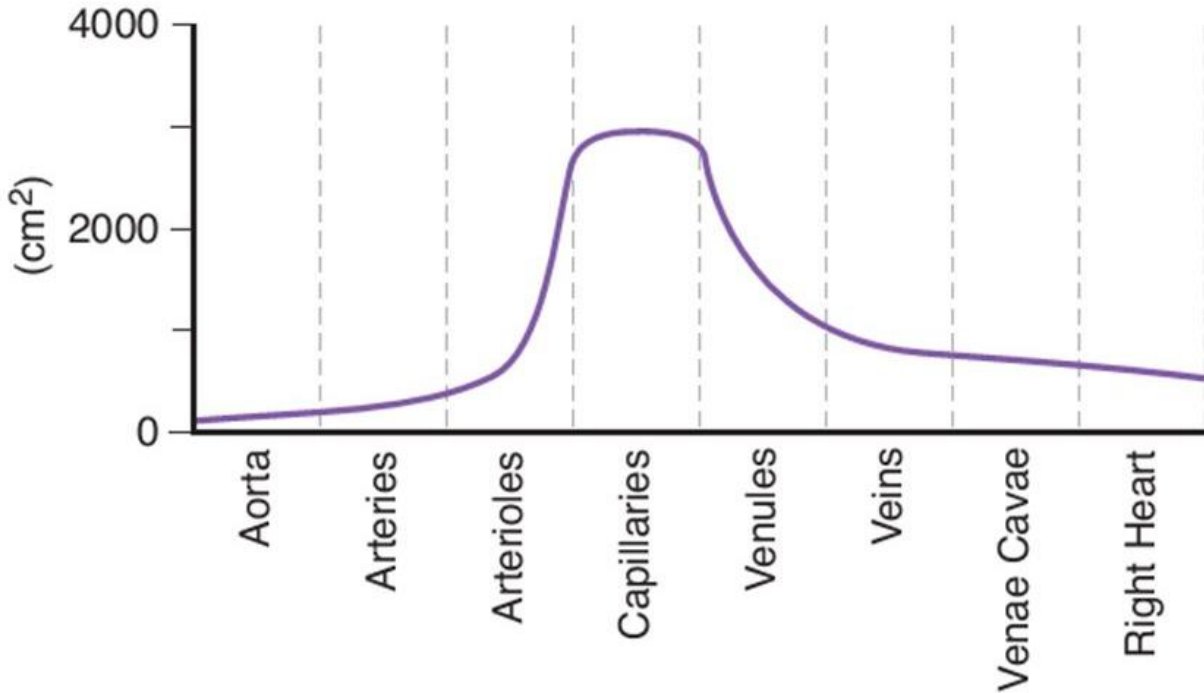
- Temperature control
- Venous return
- Reservoir

Anatomy and physiology



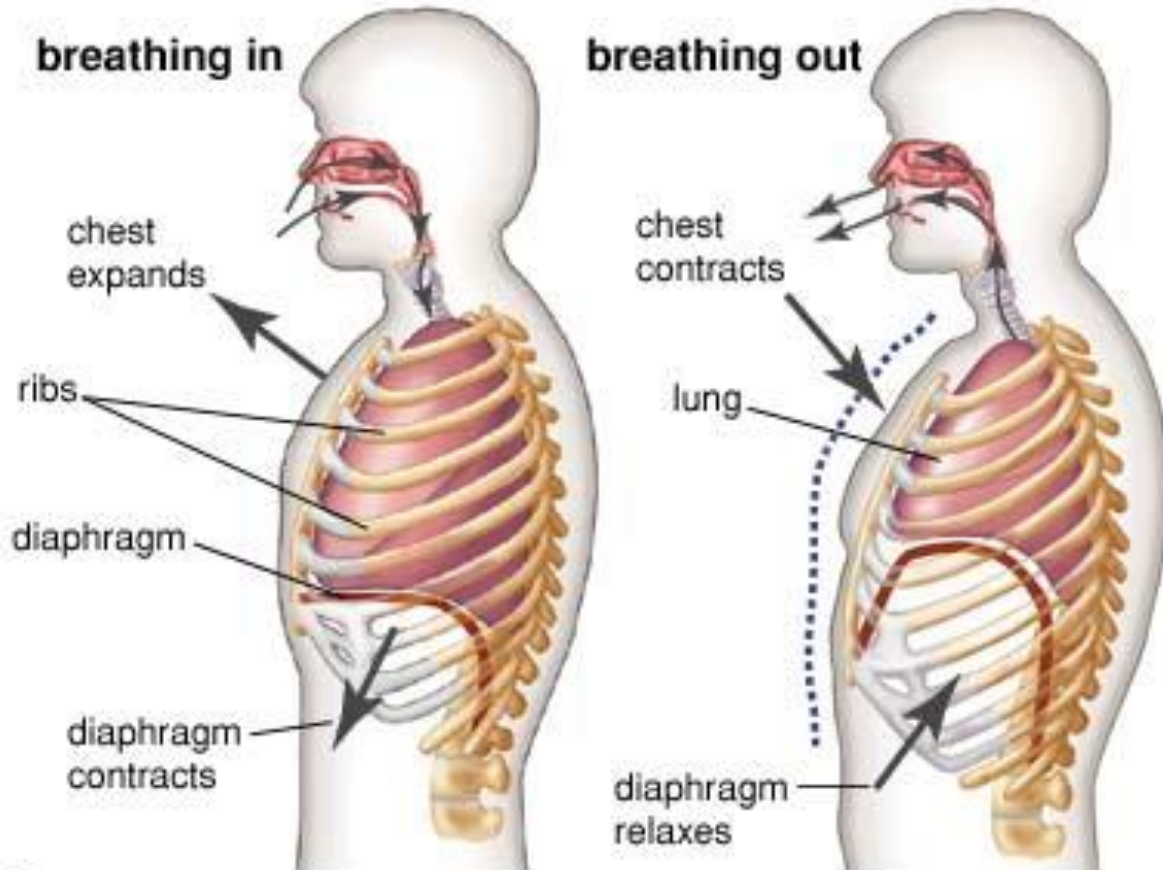
- **Vein structure**
- **Three layers**
- **Difference to artery**
- **Valve**
 - Venous return

Anatomy and physiology



- **Venous return**
- **3 mechanisms**
- **Cross-sectional area**

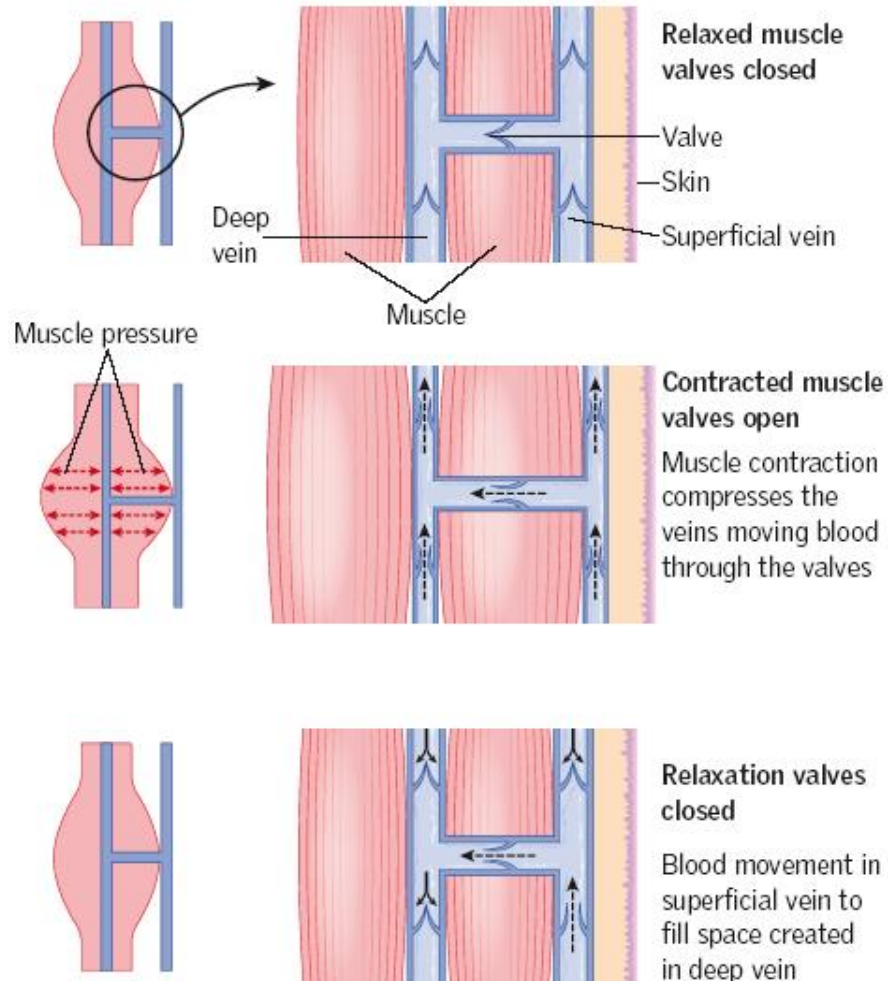
Anatomy and physiology



© 2006 Encyclopædia Britannica, Inc.

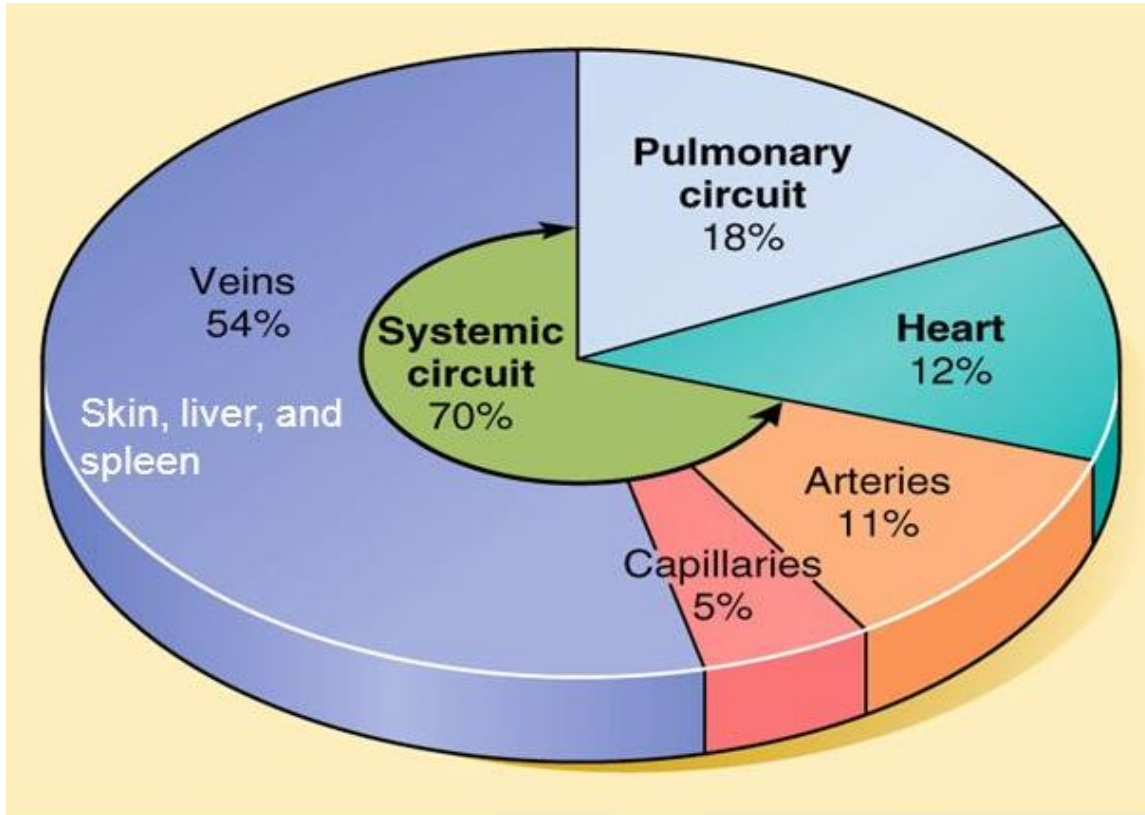
- Venous return
- 3 mechanisms
- Cross-sectional area
- Inspiration

Anatomy and physiology



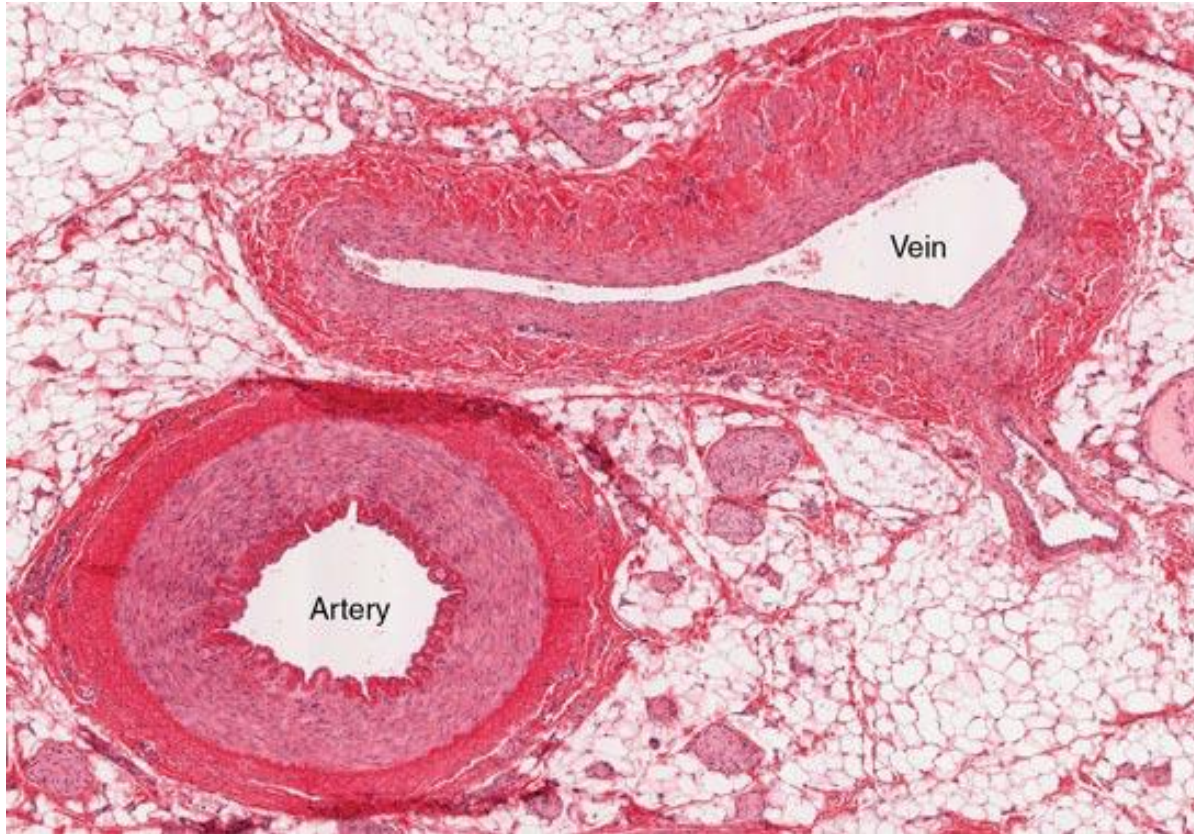- **Venous return**
- **3 mechanisms**
- **Cross-sectional area**
- **Inspiration**
- **Calf muscle pump**

Anatomy and physiology



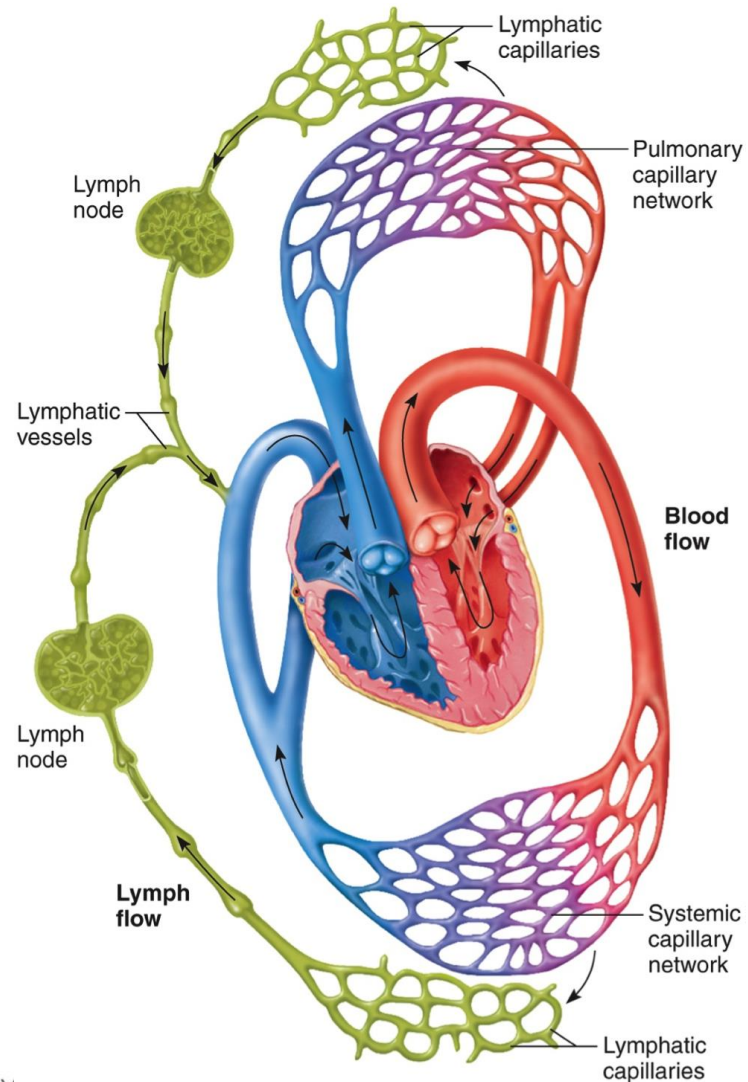
- **Venous system**
- **Function**
 - Temperature control
 - Venous return
 - Reservoir

Anatomy and physiology



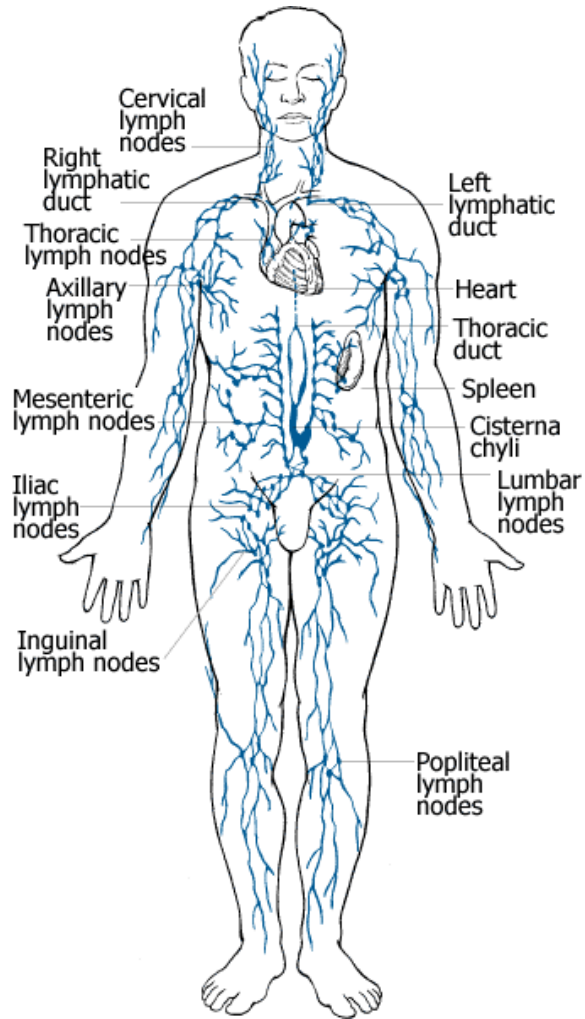
- **Venous system**
- **Function**
 - Temperature control
 - Venous return
 - Reservoir

Anatomy and physiology



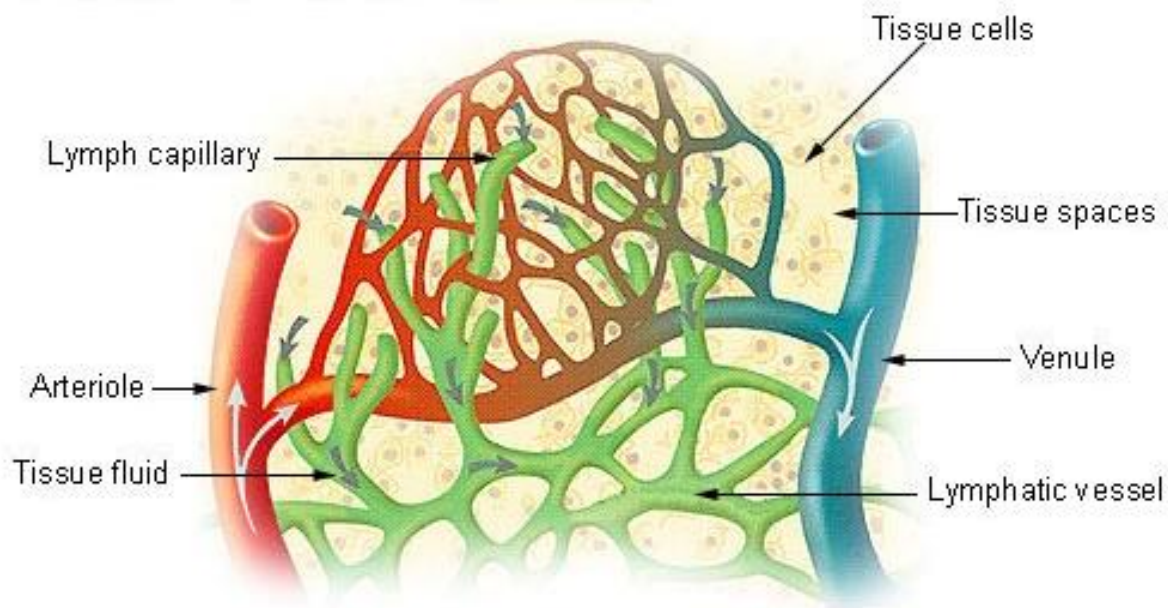
- **Lymphatic system**
- **Function**
 - Fluid management
 - Immunity

Anatomy and physiology



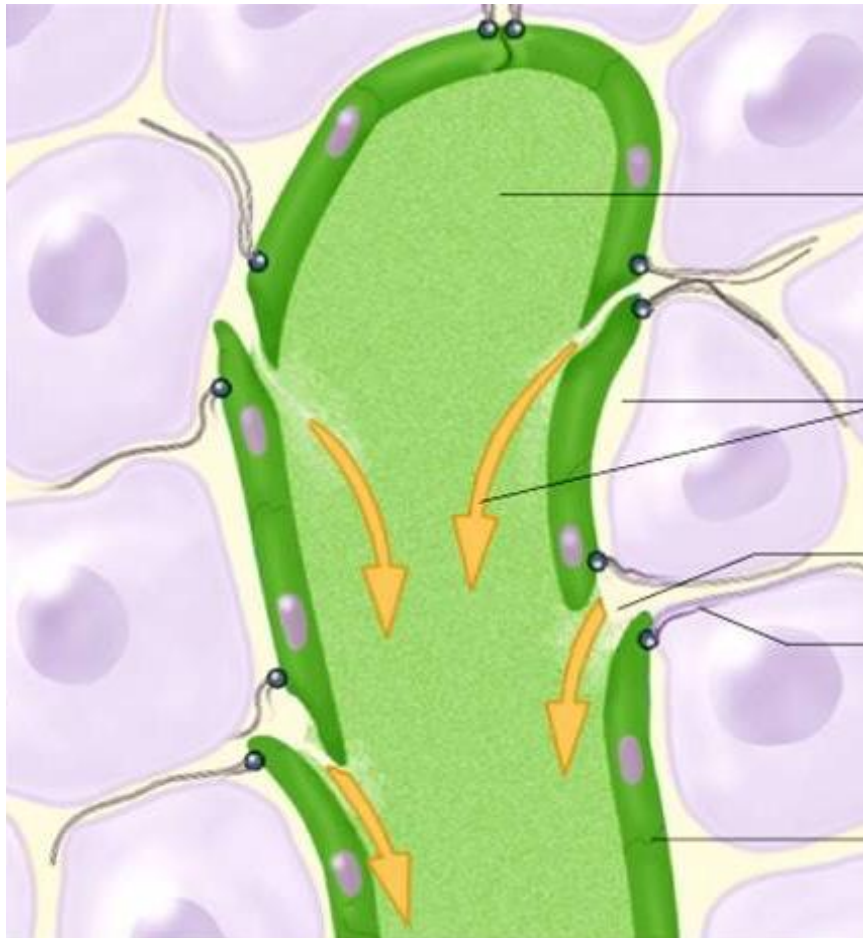
- **Lymphatic system**
- **Function**
 - Fluid management
- **2 lymphatic ducts**
- **Fluid to venous system**

Anatomy and physiology



- **Lymphatic system**
- **Function**
 - Fluid management
- **20 L capillaries**
- **3 L lymph system**

Anatomy and physiology



Lymph

Tissue fluid

Opening

Anchoring
filament

Endothelium

- **Lymph structure**

- **Openings**

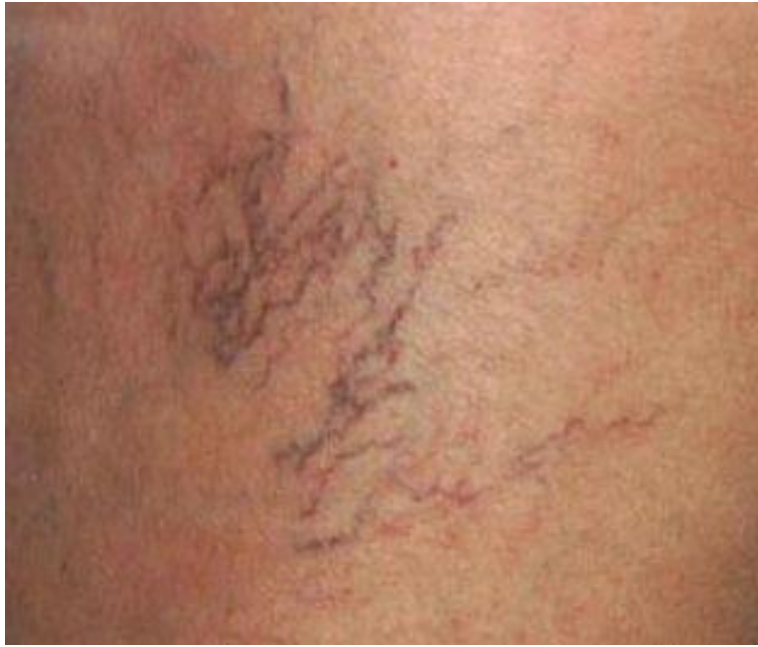- Allows proteins
- Large particles (debris, cancer)

- **Lymph return**

- Inspiration
- Calf muscles

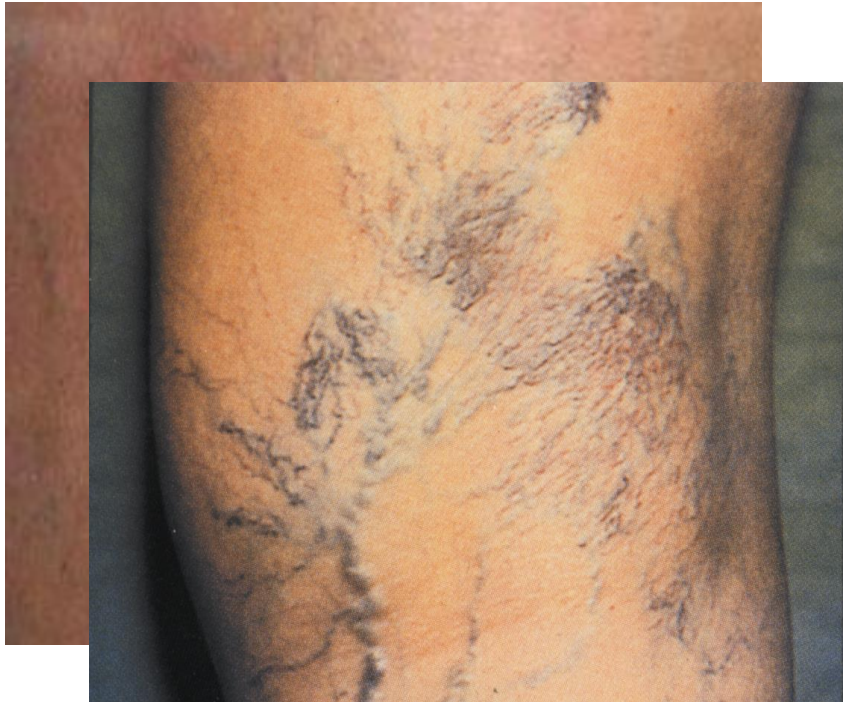- **Valves**

Pathophysiology



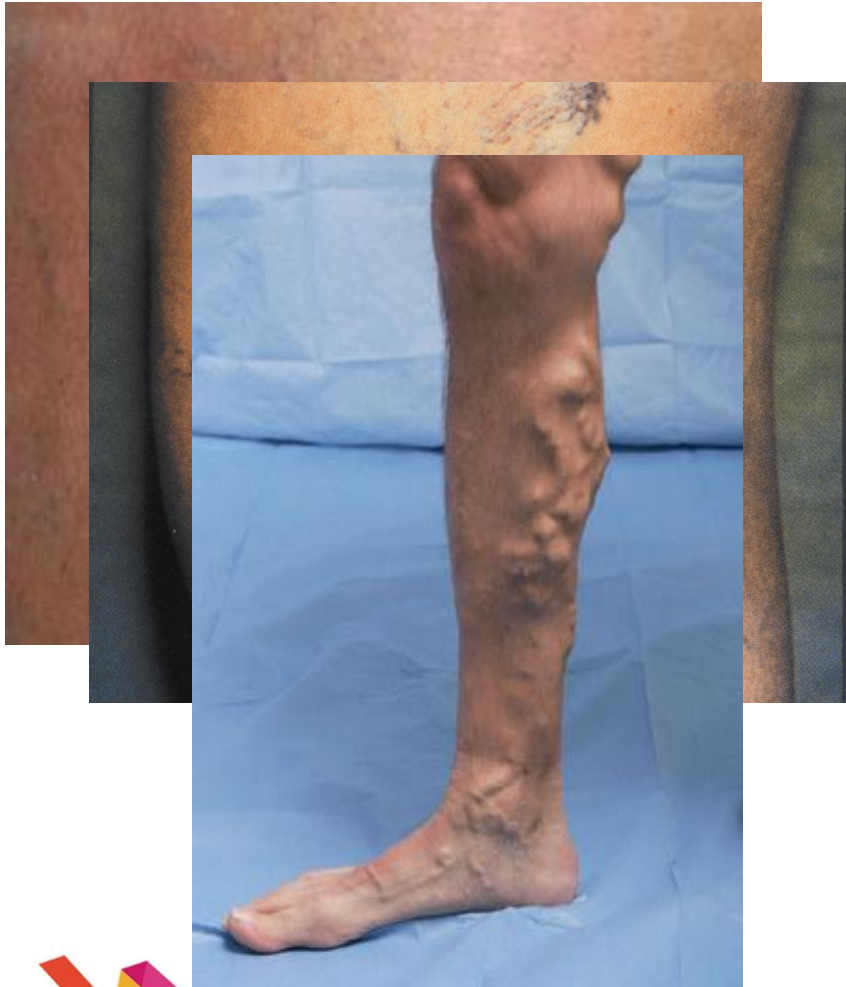- **Venous disorders**
- **Telangiectasis**

Pathophysiology



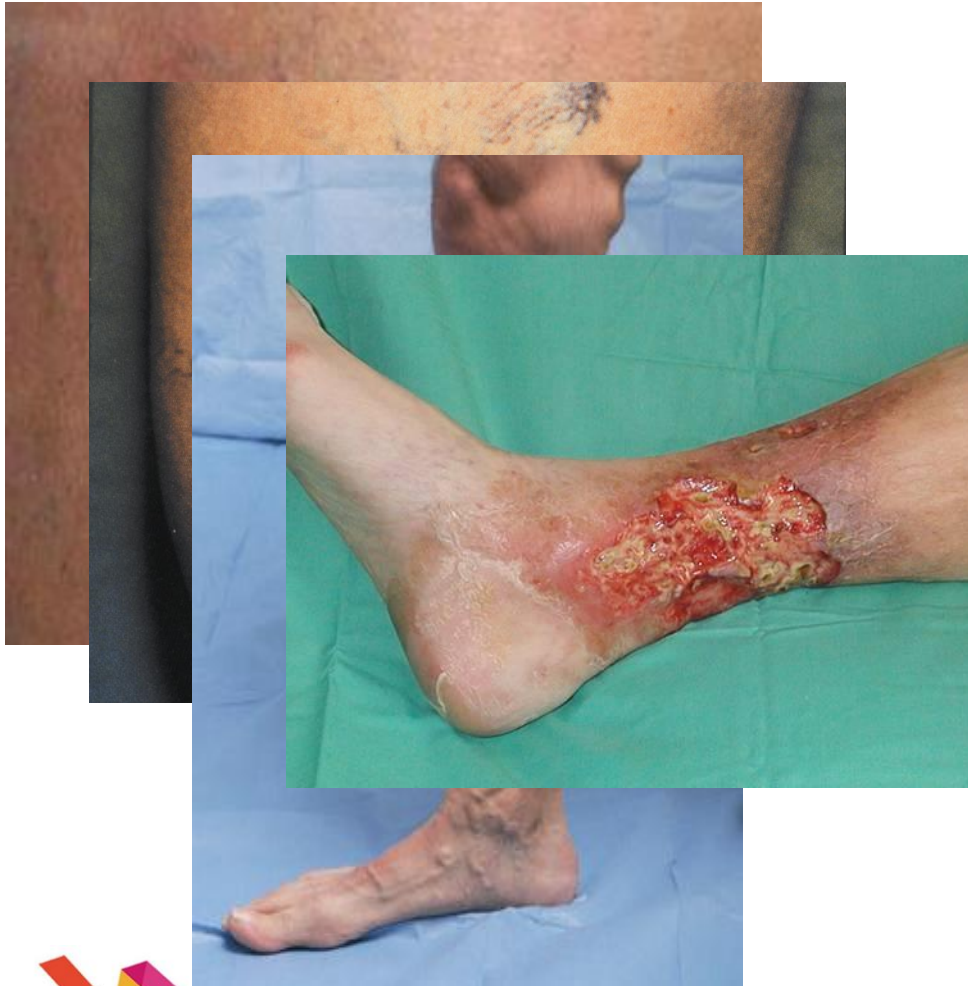- **Venous disorders**
- **Telangiectasis**
- **Reticular veins**

Pathophysiology



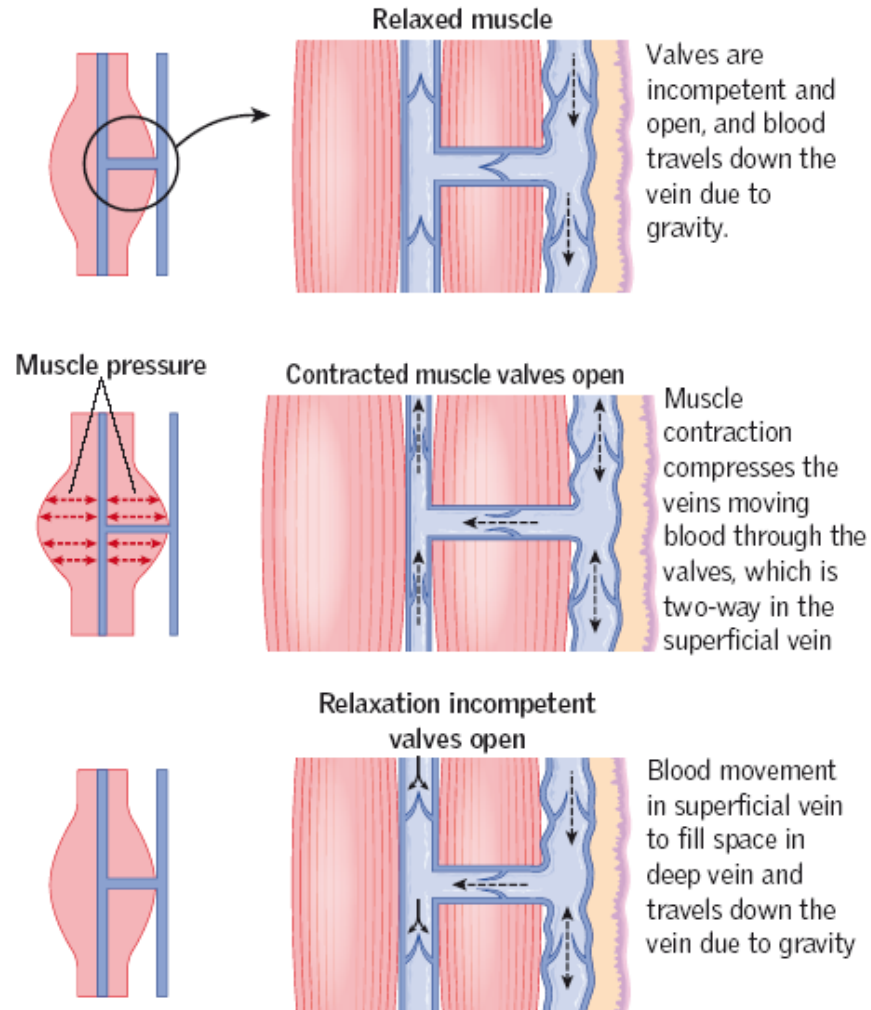
- **Venous disorders**
- **Telangiectasis**
- **Reticular veins**
- **Varicose veins**

Pathophysiology



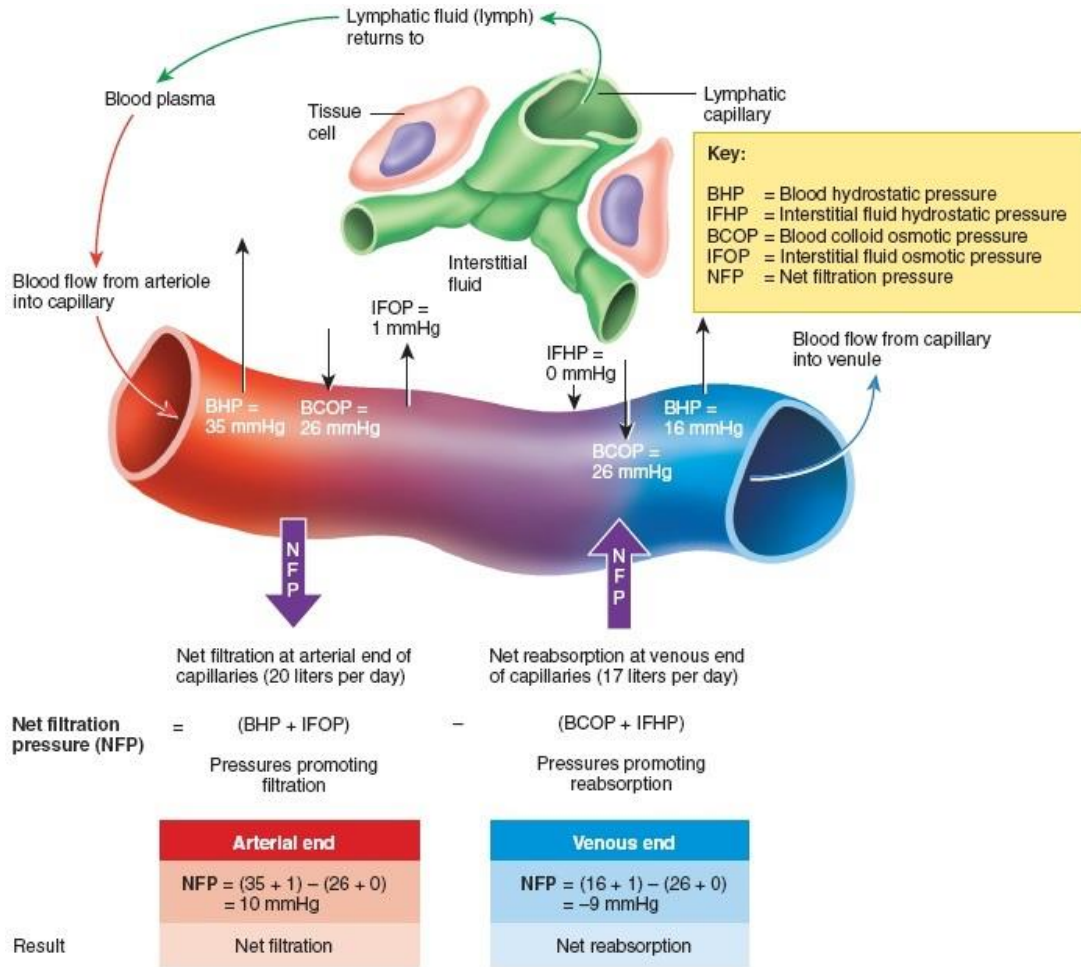
- **Venous disorders**
- **Telangiectasis**
- **Reticular veins**
- **Varicose veins**
- **Venous ulceration**

Pathophysiology



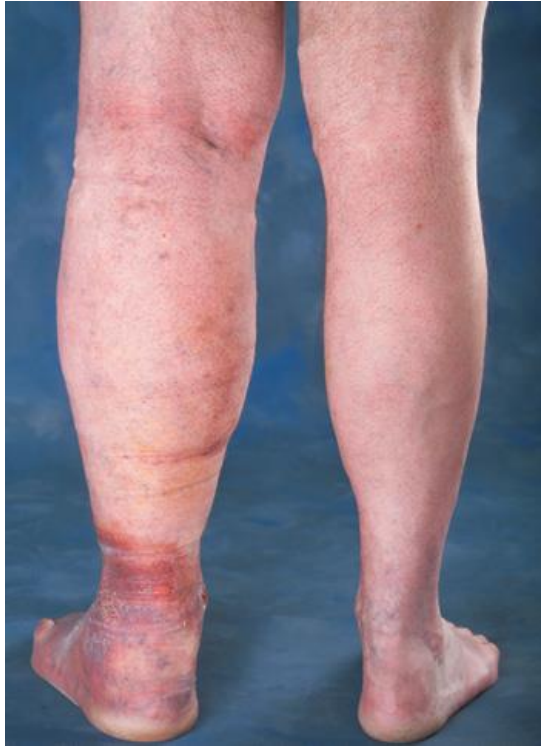- **Venous disorders**
- **Varicose veins**
- **Calf pump dysfunction**
 - Shuffle walking
 - Injury

Pathophysiology



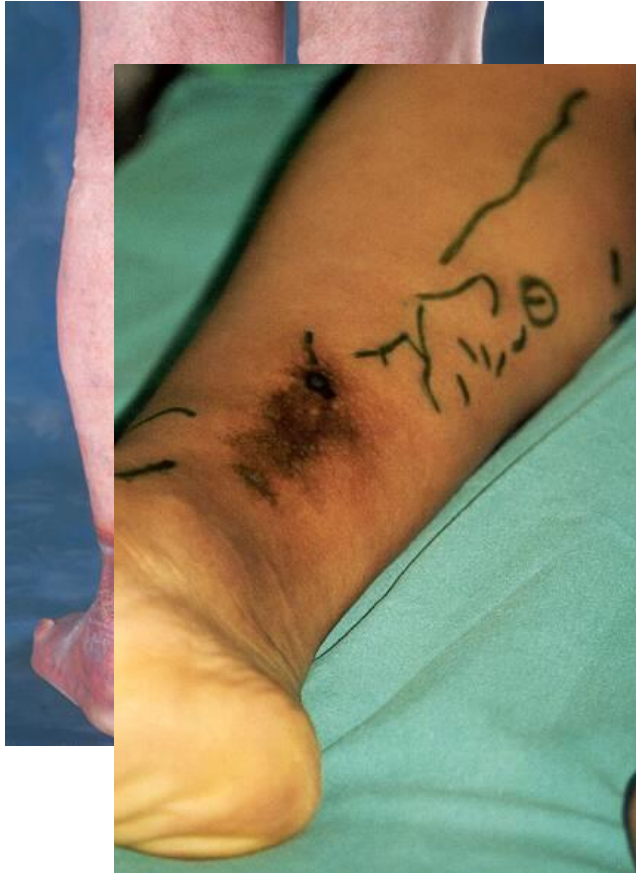- Venous disorders
- Varicose veins
- Calf pump dysfunction
 - Shuffle walking
 - Injury
- Venous hypertension
- Chronic venous insufficiency

Pathophysiology



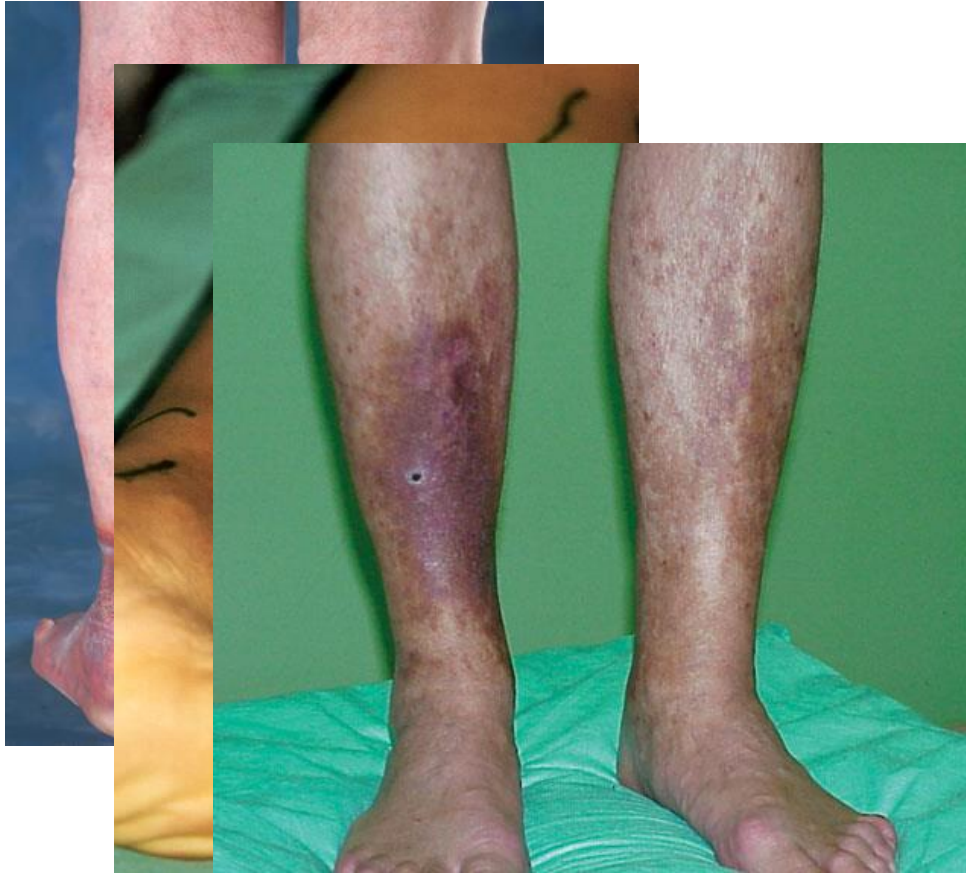
- **Venous disorders**
- **Chronic Venous insufficiency**
 - Oedema

Pathophysiology



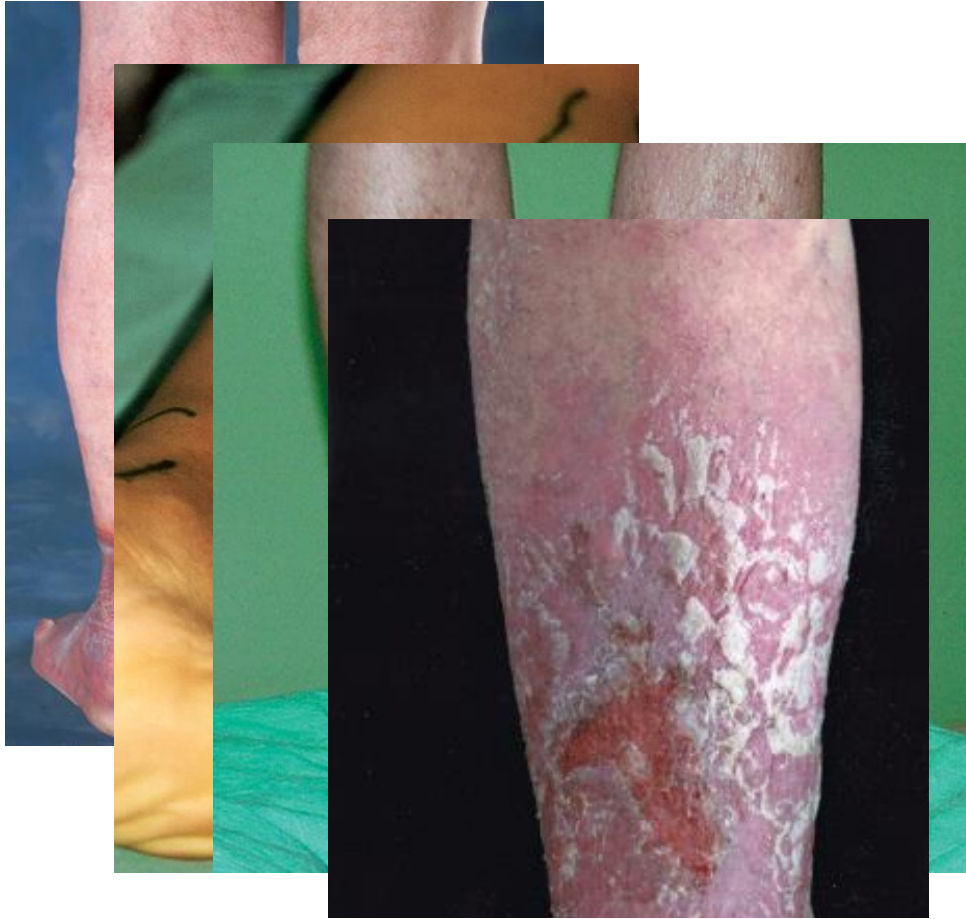- **Venous disorders**
- **Chronic Venous insufficiency**
 - Oedema
 - Haemosiderin staining

Pathophysiology



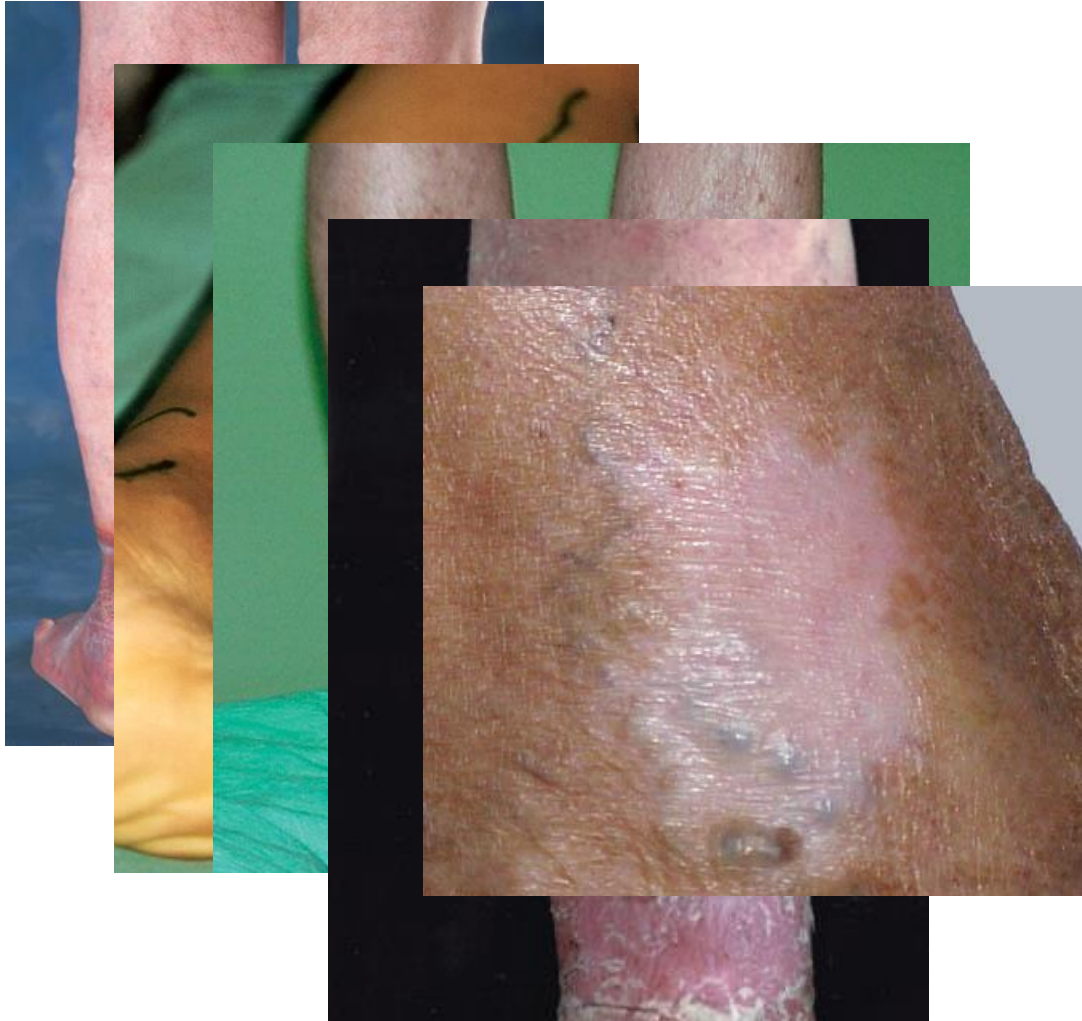
- **Venous disorders**
- **Chronic Venous insufficiency**
 - Oedema
 - Haemosiderin staining
 - Lipodermatosclerosis

Pathophysiology



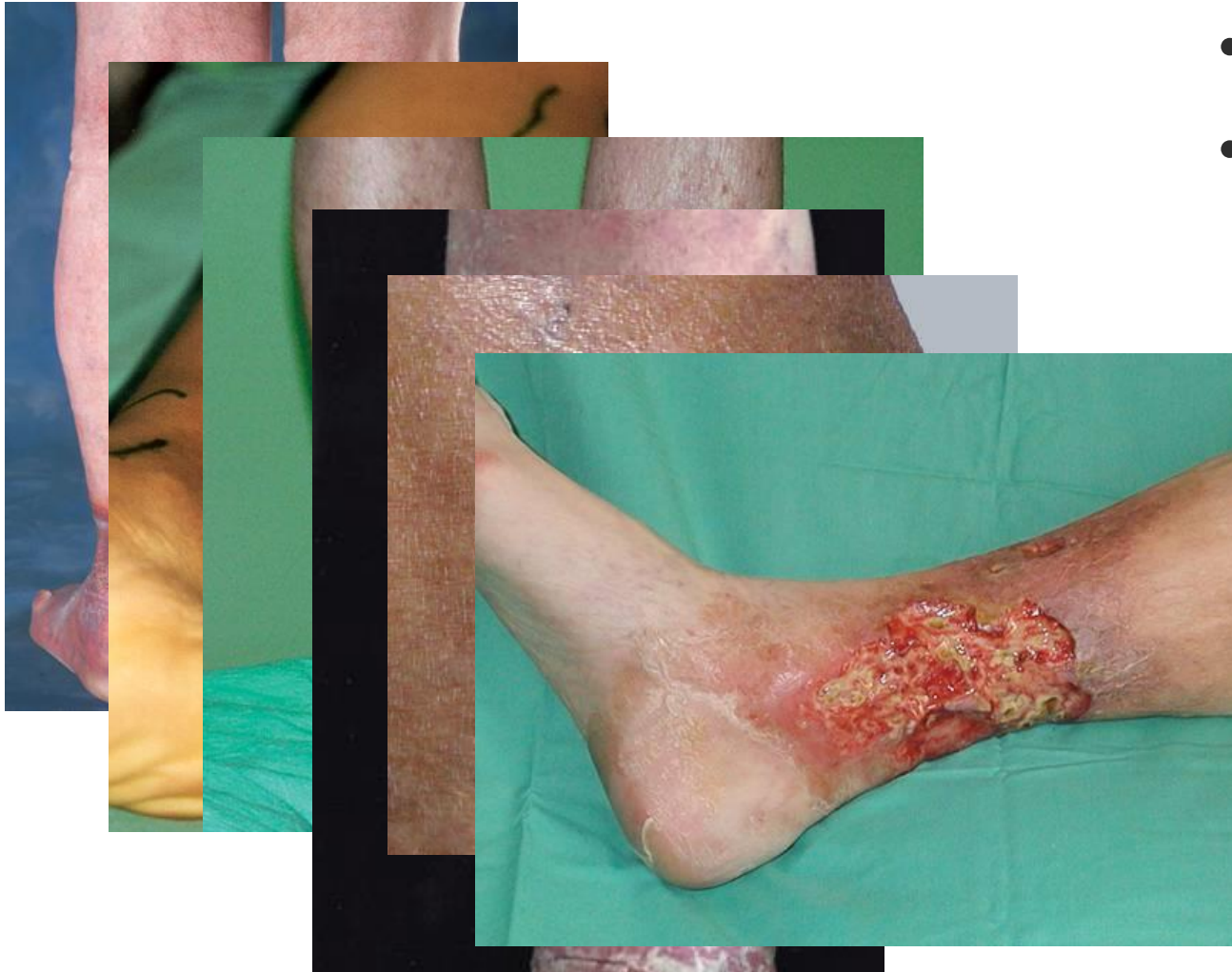- **Venous disorders**
- **Chronic Venous insufficiency**
 - Oedema
 - Haemosiderin staining
 - Lipodermatosclerosis
 - Varicose eczema

Pathophysiology



- **Venous disorders**
- **Chronic Venous insufficiency**
 - Oedema
 - Haemosiderin staining
 - Lipodermatosclerosis
 - Varicose eczema
 - Atrophie blanche

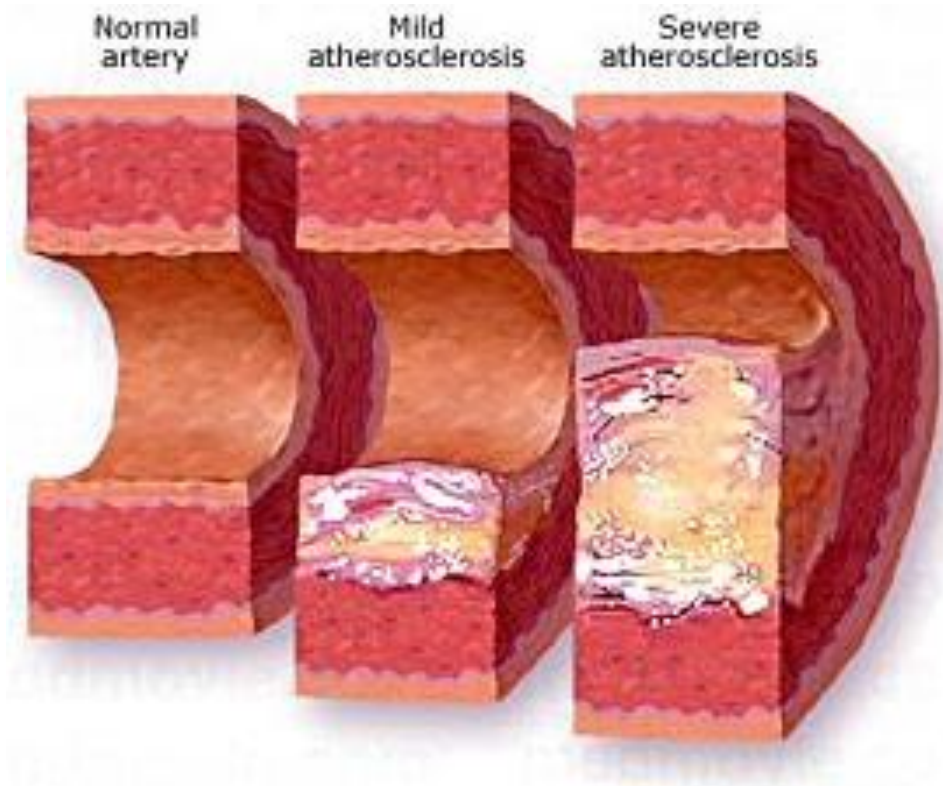
Pathophysiology



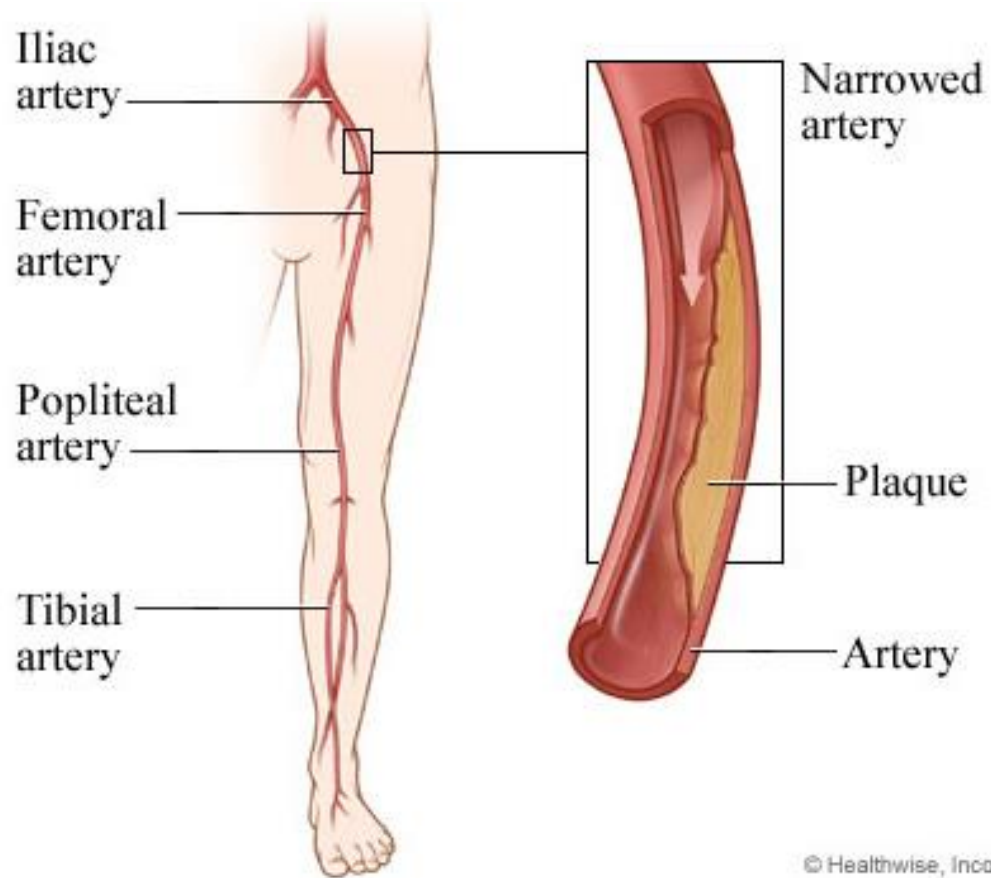
- **Venous disorders**
- **Chronic Venous insufficiency**
 - Oedema
 - Haemosiderin staining
 - Lipodermatosclerosis
 - Varicose eczema
 - Atrophie blanche
 - Venous ulceration

Pathophysiology

- Arterial disorders
- Atherosclerosis



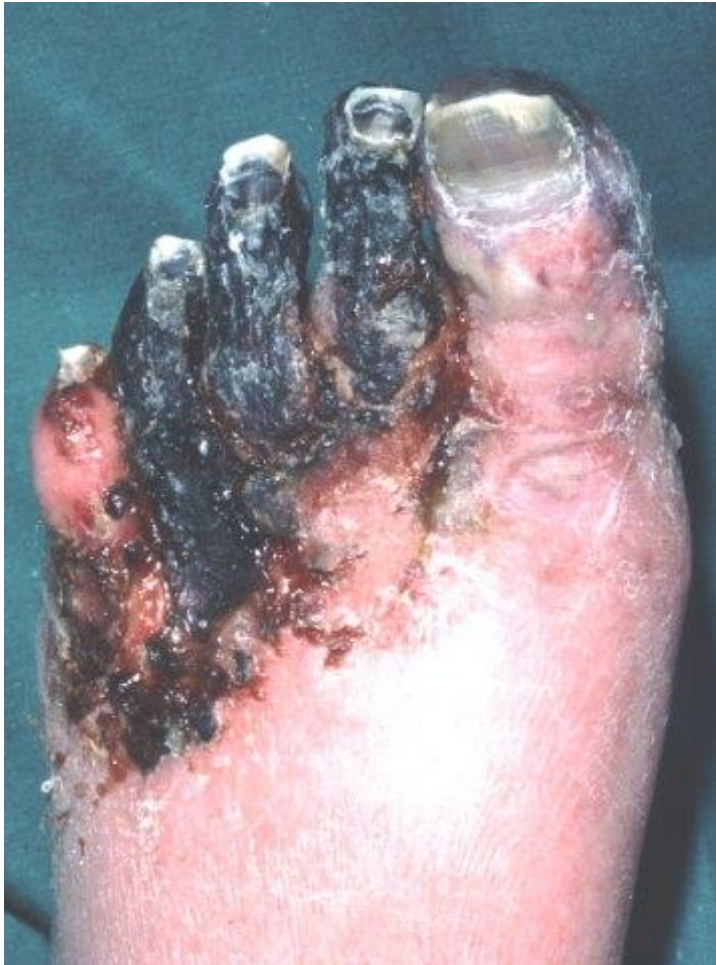Pathophysiology



© Healthwise, Inc.

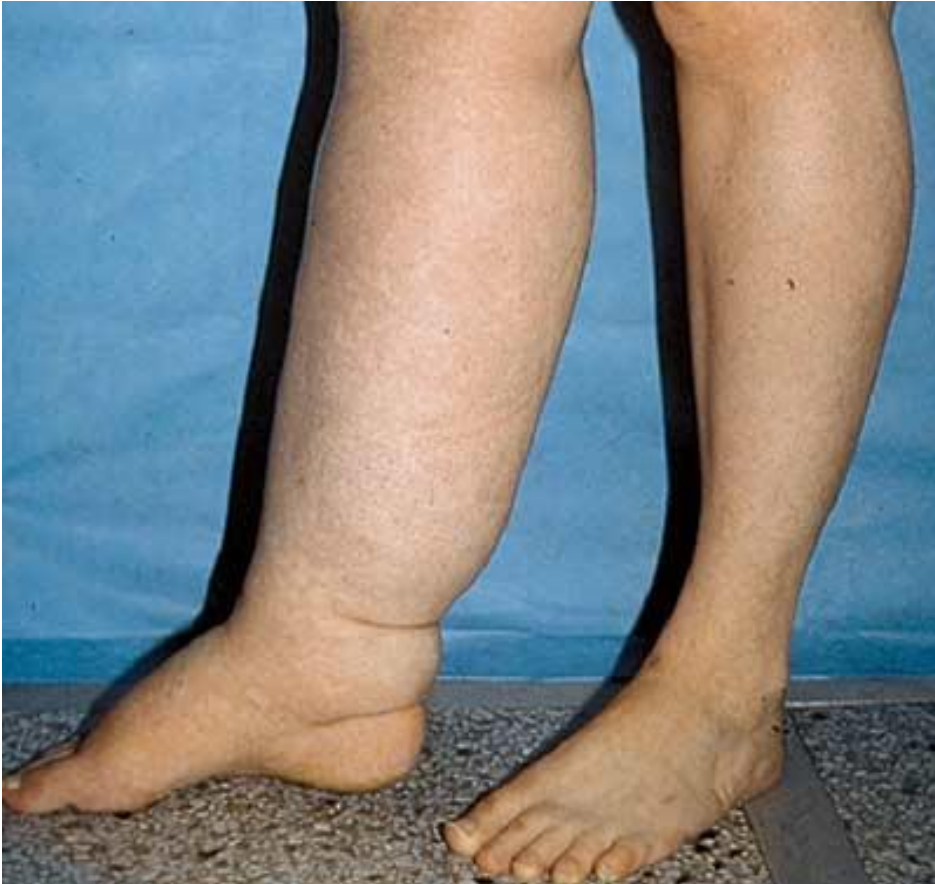- **Arterial disorders**
- **Atherosclerosis**
- **Peripheral vascular disease (PVD)**
 - Intermittent claudication
 - Nocturnal pain
 - Rest pain
 - Critical limb ischaemia (CLI)

Pathophysiology



- **Arterial disorders**
- **Atherosclerosis**
 - Critical limb ischaemia
 - Six 'P's"
 - Pallor
 - Perishingly cold
 - Paraesthesia
 - Paralysis
 - Pain
 - Pulselessness

Pathophysiology



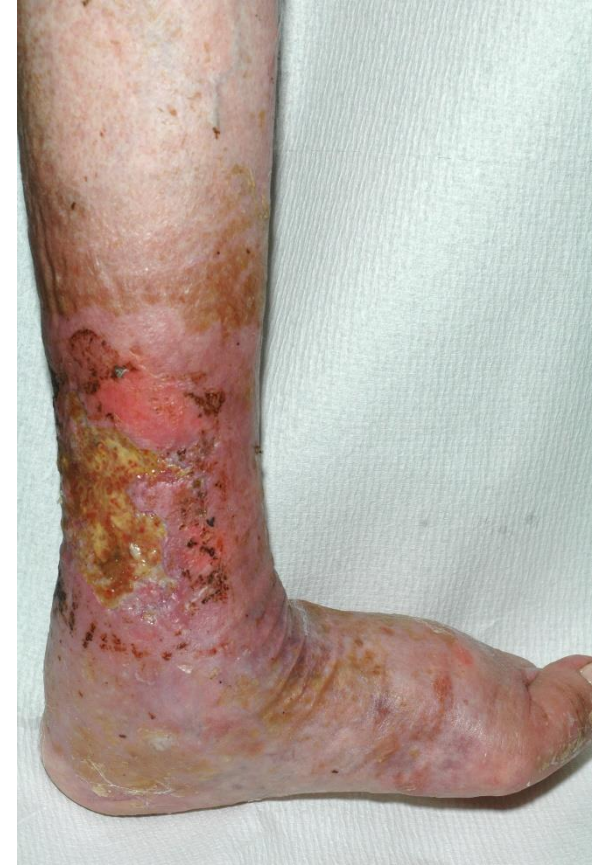- **Lymph disorders**
- **Lymphoedema**
 - Obstruction
 - Fluid management
 - Primary
 - Secondary

Mixed Ulceration: What you need to know

Dr Leanne Atkin

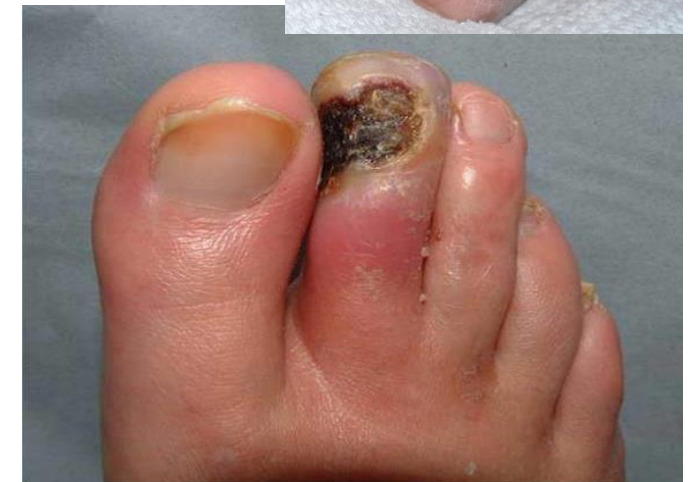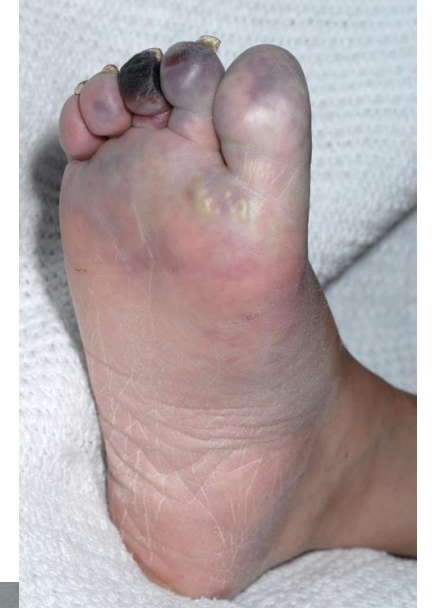Mixed disease

- **Identification is the key**
- **Which factor is involved:**
 - Venous
 - Arterial
 - Lymphoedema



Chronic limb threatening ischaemia

- Often has background of claudication
- Dependent rubor — red sunset foot — reduces on elevation
- Associated with severe pain (unless diabetic)
- Inability to sleep in bed
- If revascularisation not timely, tissue loss will follow
- Tissue loss often necrotic and on foot
- No need for urgent admission
- Requires urgent referral to vascular team



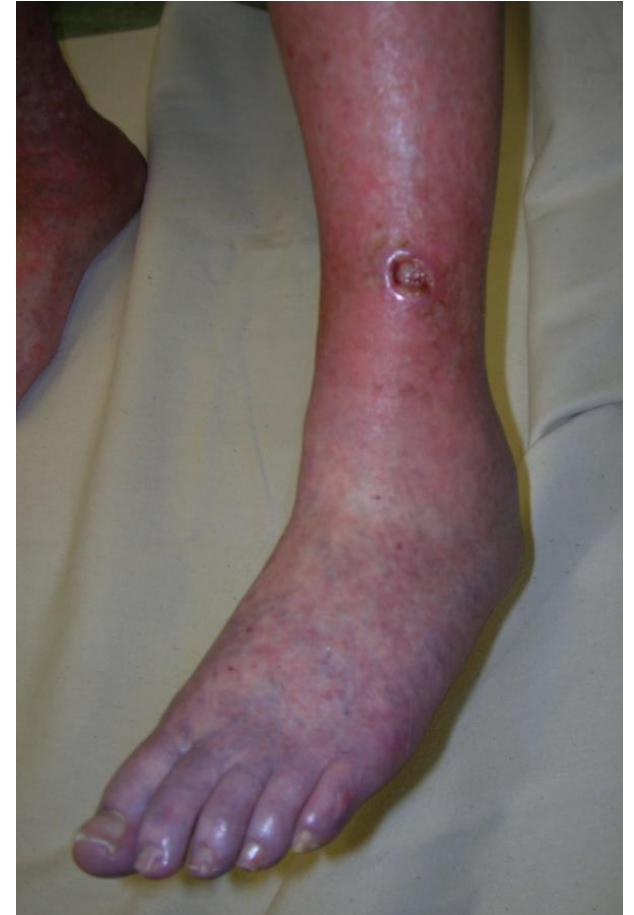Arterial ulceration

Limb:

- Shiny skin
- Mainly occurs on the foot/lateral aspect of limb
- Hairless skin and thick toenails
- Localised oedema
- Develops quickly

Ulcer:

- Has a punched out appearance
- Circular appearance
- Painful



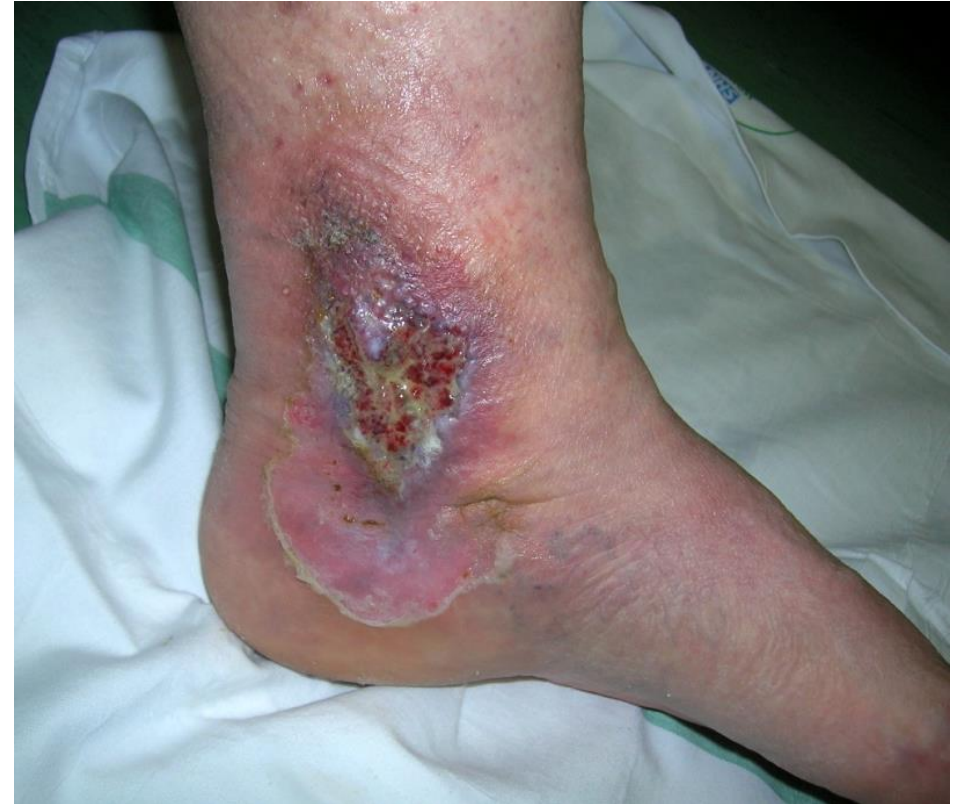Venous ulceration

Limb:

- Varicose veins
- Venous eczema
- Haemosiderin staining
- Lipodermatosclerosis
- Oedema

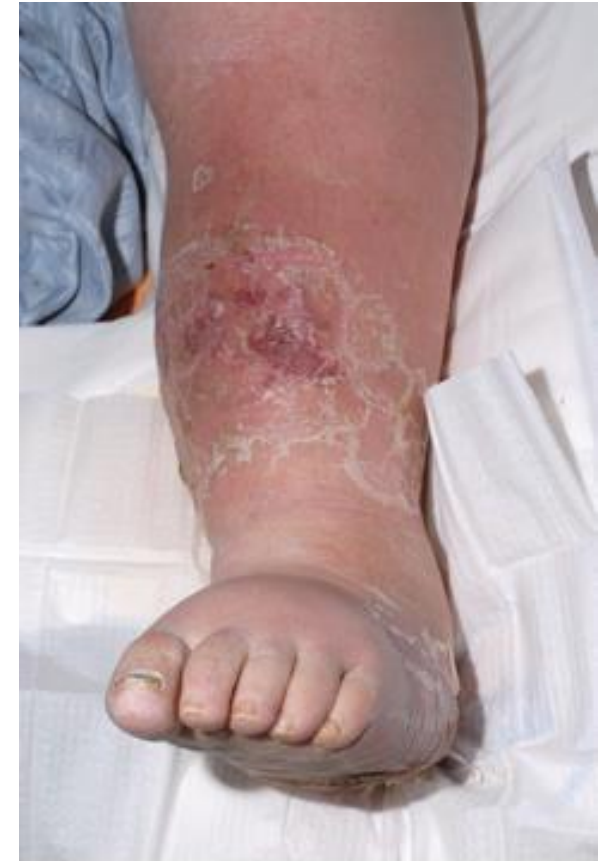Ulcer:

- Irregular shape, shallow in depth
- Moderate/high volume of exudate
- Gaiter/malleolus region



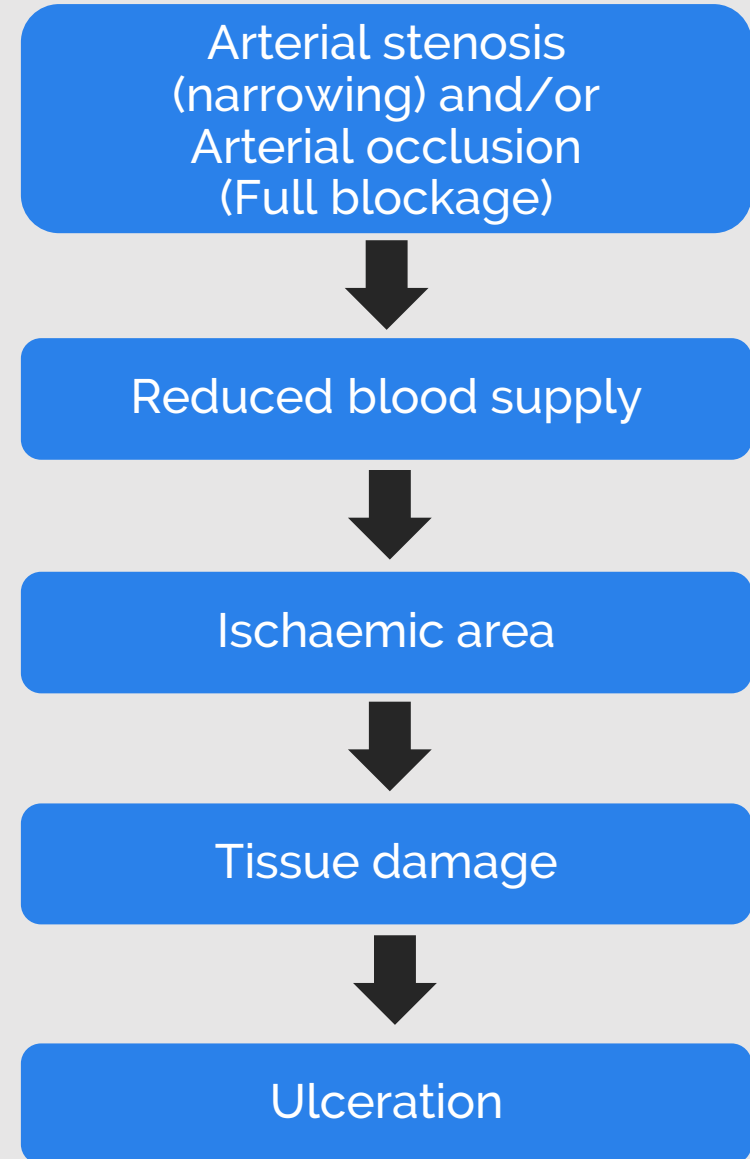
Oedema

- Initially soft and pitting
- Chronic skin changes
- Fibrosis in tissue
- Eczema
- Hyperkeratosis
- Lipermatosclerosis
- Lymphorrhoea – ‘wet legs’
- Risk of skin breakdown/ulceration



Causes of arterial ulcers

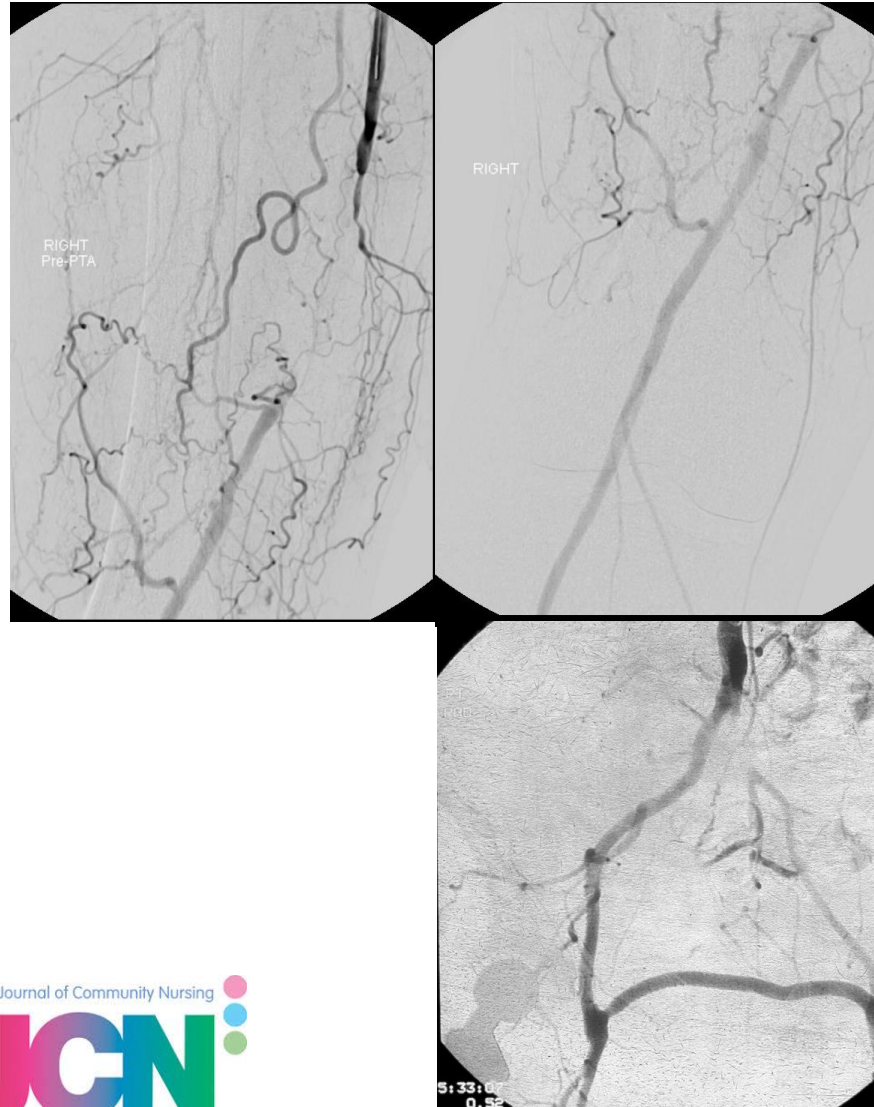
Arterial insufficiency



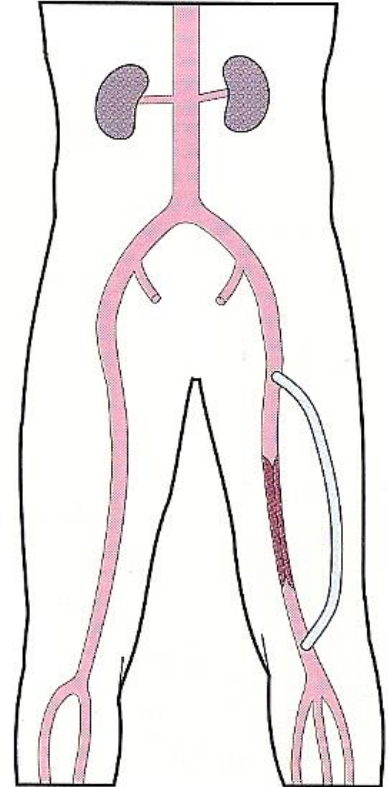
Treatment of arterial disease

Revascularisation:

- Angioplasty
- Bypass surgery

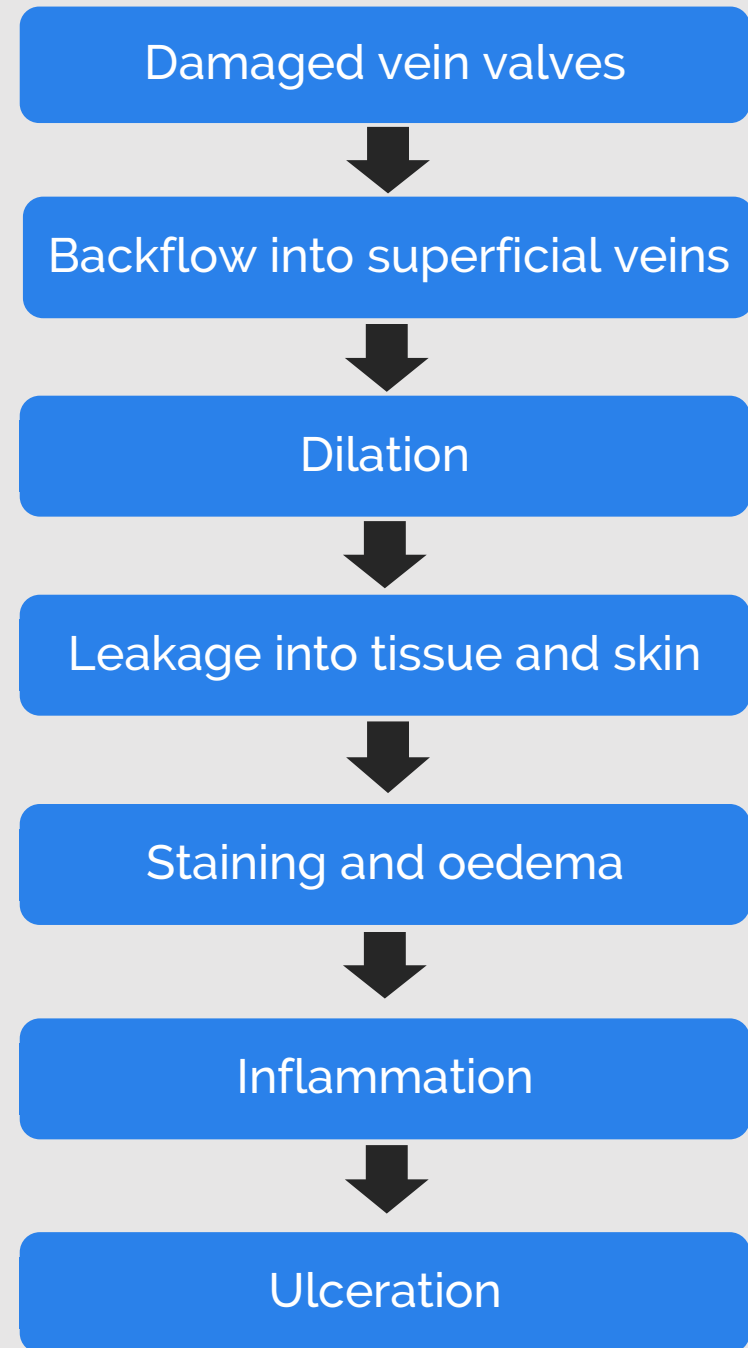
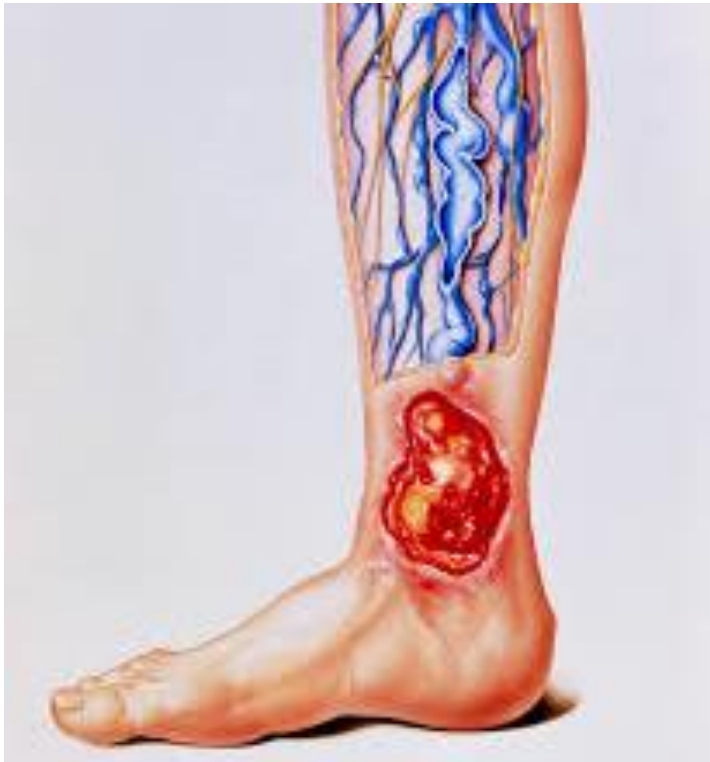

D Femoro-popliteal



Pathophysiology of venous leg ulcers

Venous hypertension



Treatment of venous disease

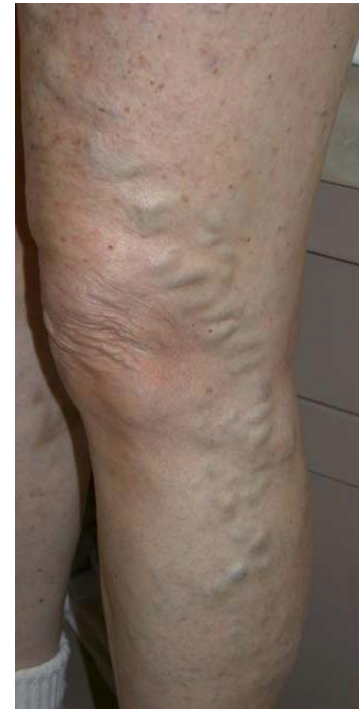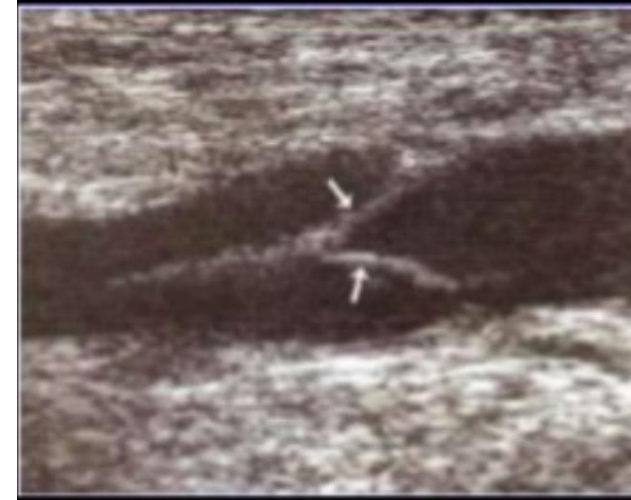Venous hypertension — why?

Structural:

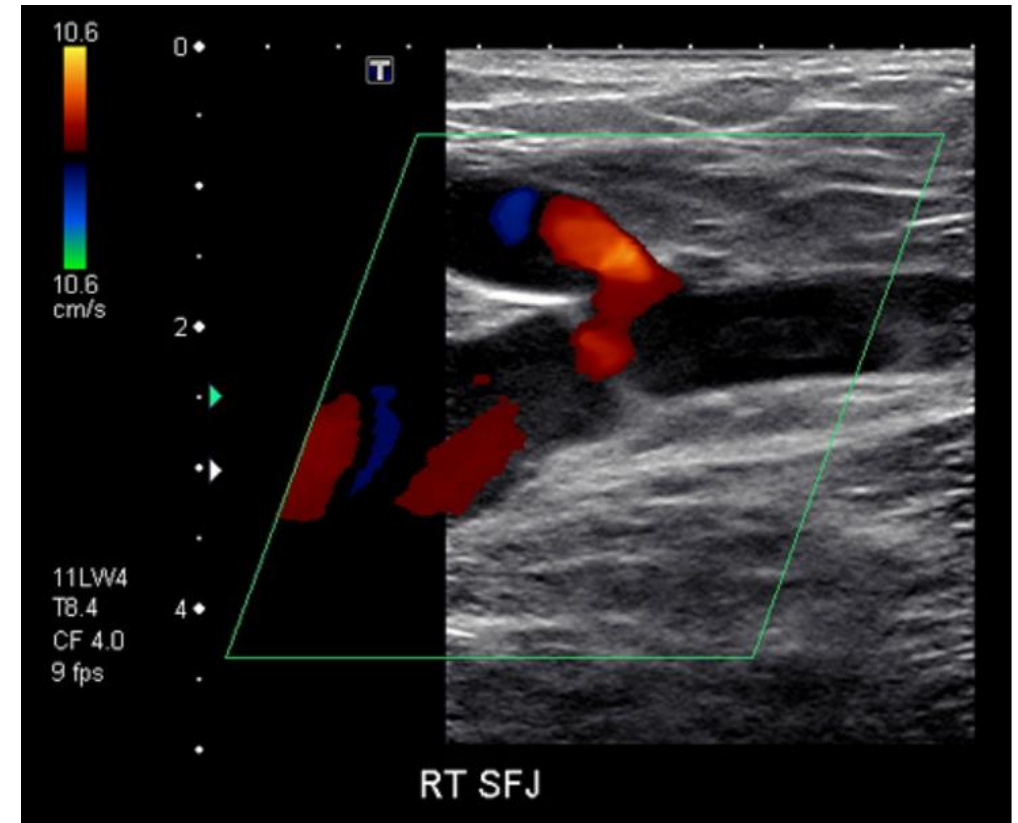
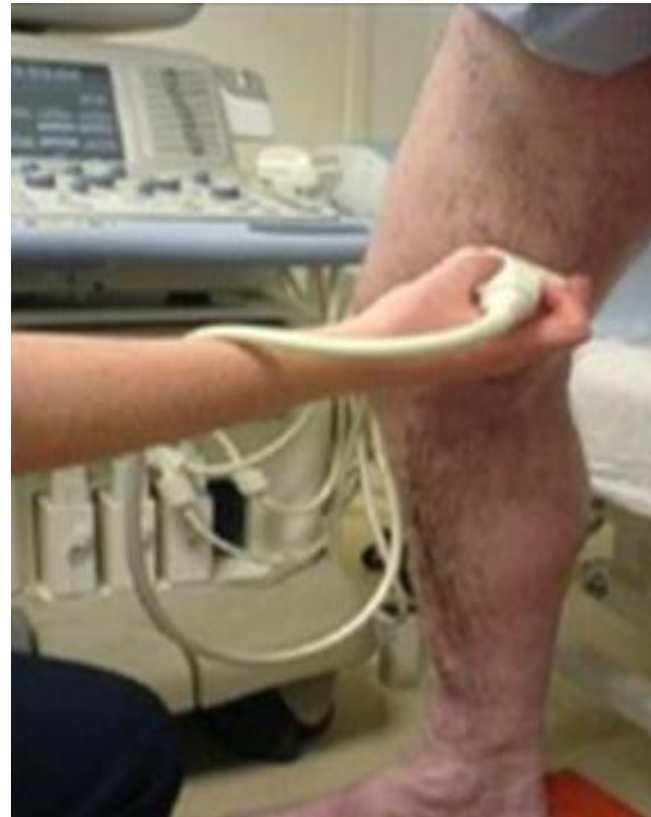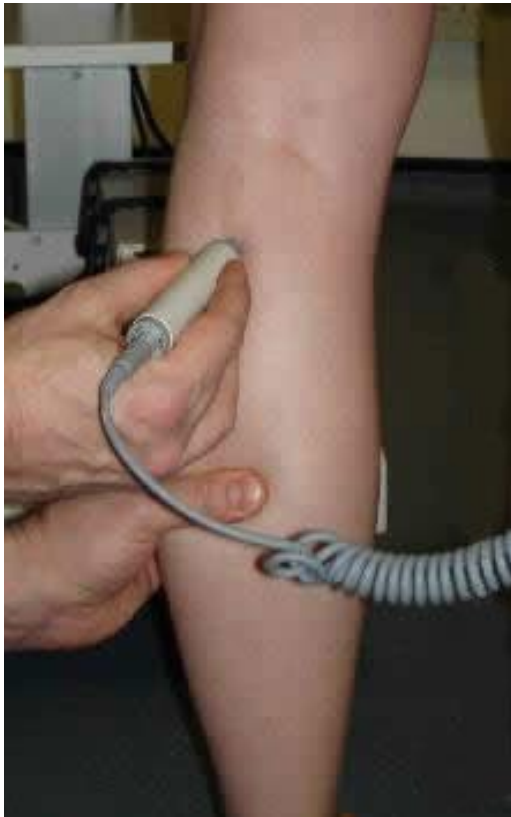- Valve incompetence
- Venous obstruction

Functional:

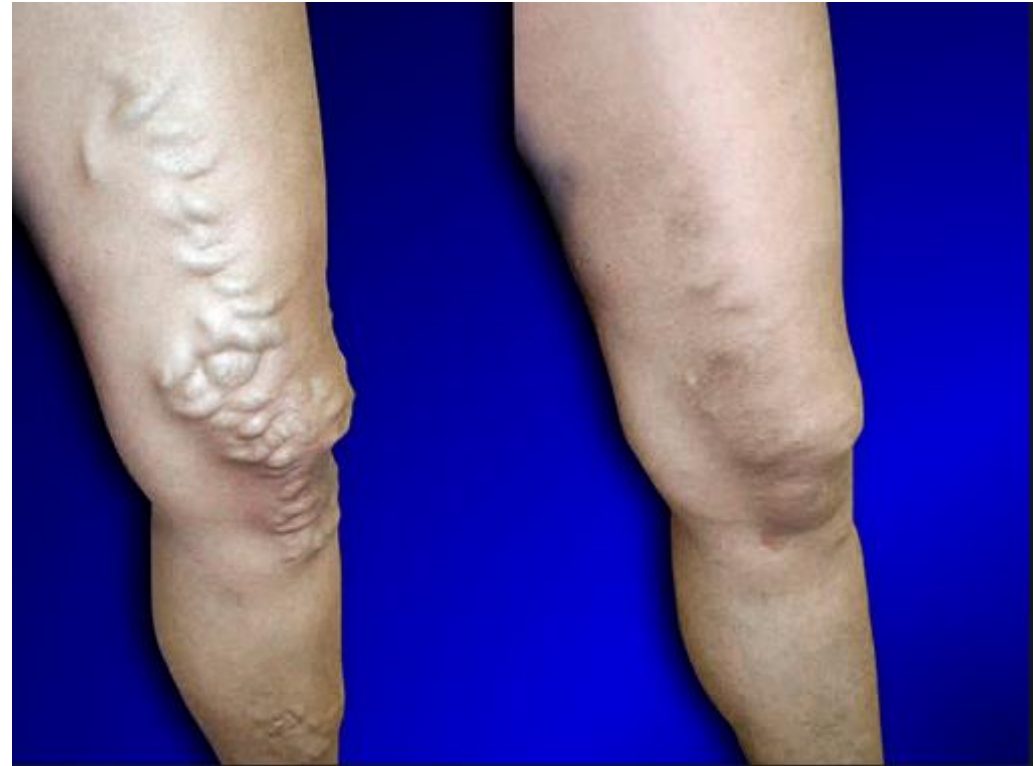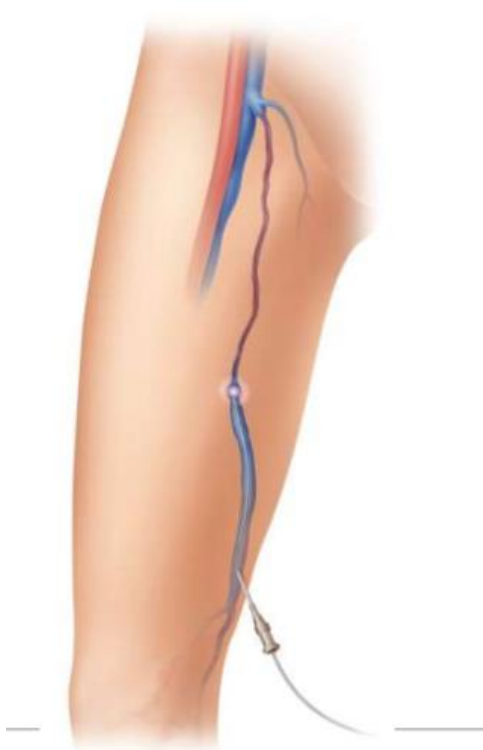- Dependency
- Loss of foot/calf muscle pump



Venous hypertension: assessment



Venous ablation

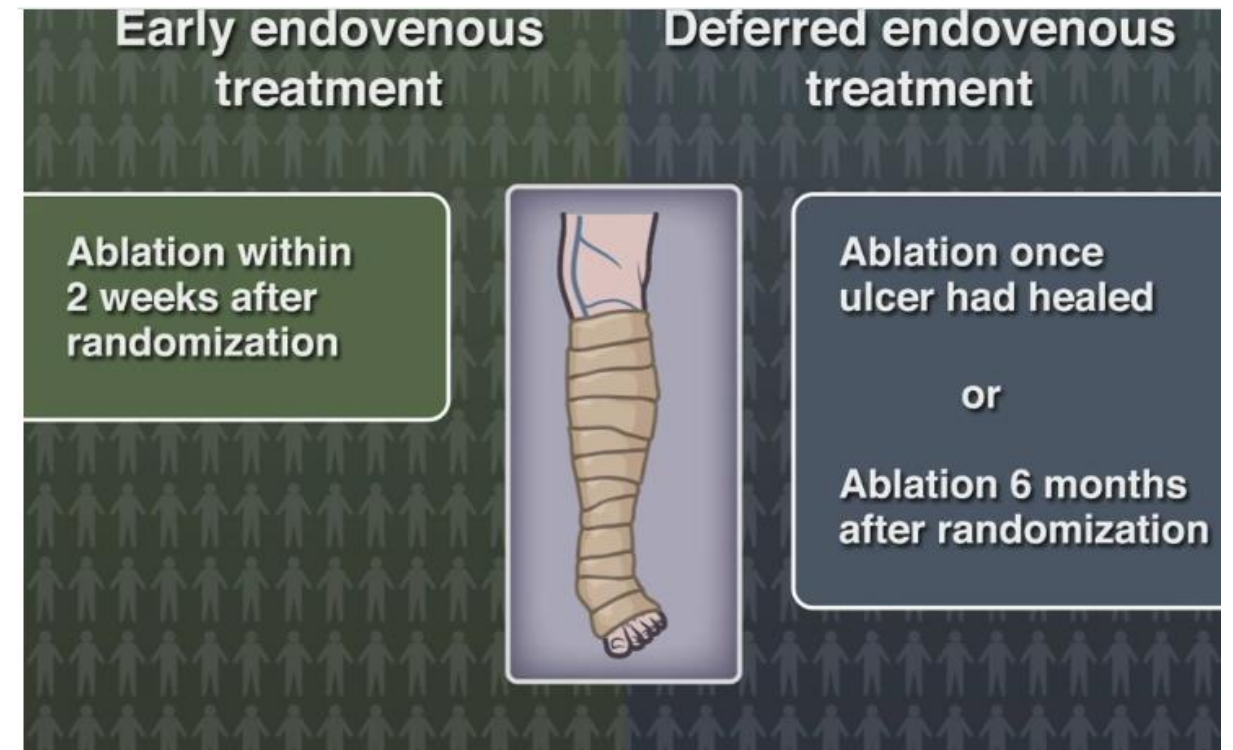


Minimally invasive, walk in walk out, one incision, local only, less pain, less bruising, immediate return to work.

Treatment: venous ablation

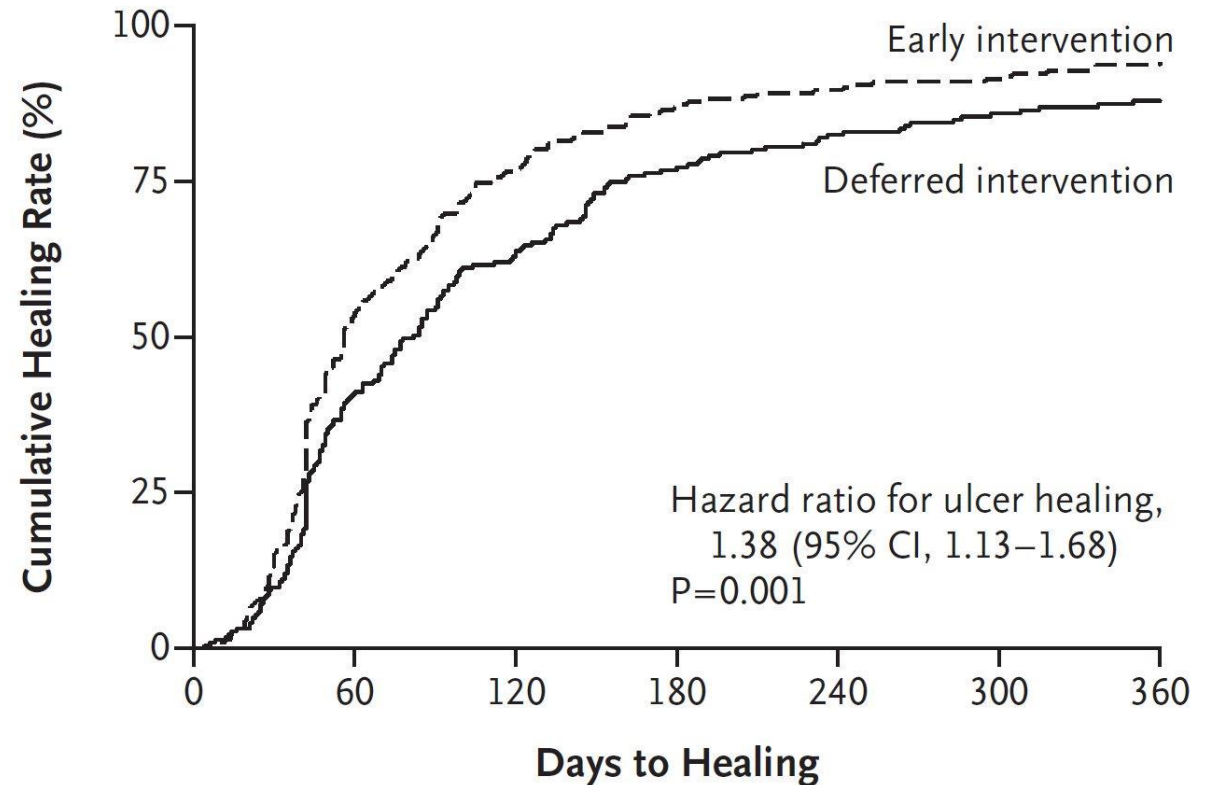
- **Multicentre RCT**
- **Parallel group**
- **450 patients**
- **Superficial venous reflux**
- **Venous leg ulcers**

E  **RA**



EVRA results

- Early venous intervention aids healing
- Healing times reduced from 82 days in control group (compression) to 56 days (compression and venous intervention) (P=0.001)
- Rate of healing at 24 weeks was 85.6%



Management of venous disease

1.2 Referral to a vascular service

1.2.1 Refer people with bleeding varicose veins to a vascular service^[3] immediately.

1.2.2 Refer people to a vascular service if they have any of the following.

- Symptomatic^[4] primary or symptomatic recurrent varicose veins.
- Lower-limb skin changes, such as pigmentation or eczema, thought to be caused by chronic venous insufficiency.
- Superficial vein thrombosis (characterised by the appearance of hard, painful veins) and suspected venous incompetence.
- A venous leg ulcer (a break in the skin below the knee that has not healed within 2 weeks).
- A healed venous leg ulcer.

NICE National Institute for
Health and Care Excellence

Varicose veins in the legs

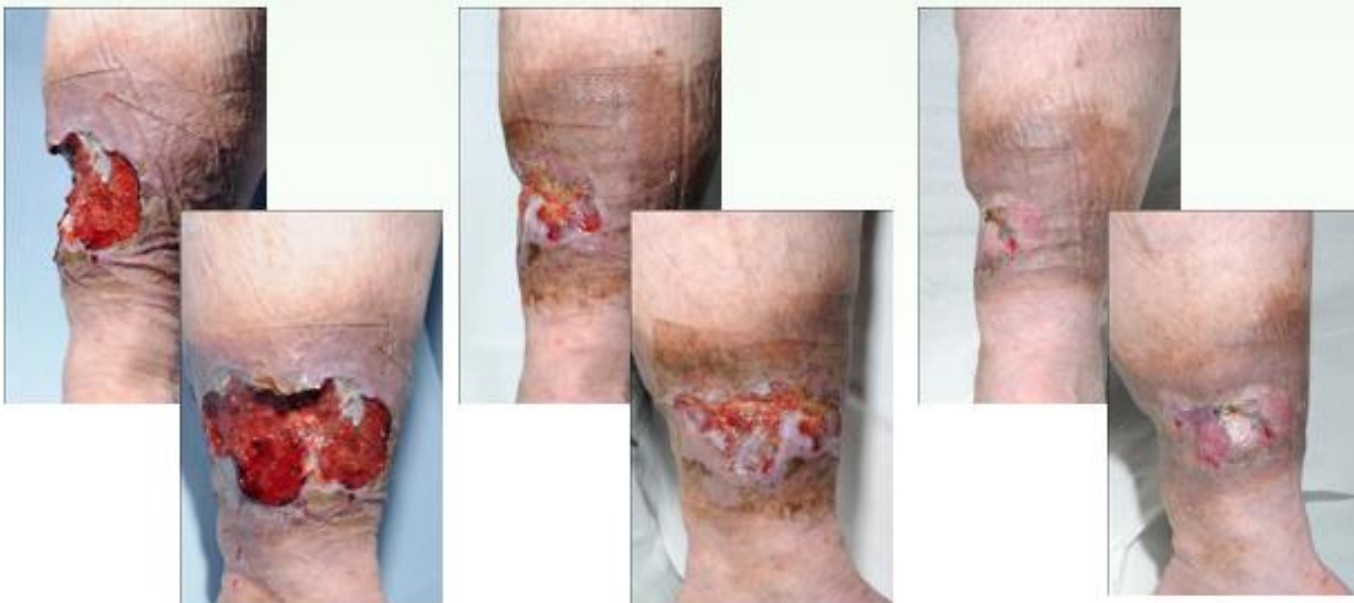The diagnosis and management of varicose veins

Issued: July 2013

NICE clinical guideline 168
guidance.nice.org.uk/cg168

Treatment: compression therapy

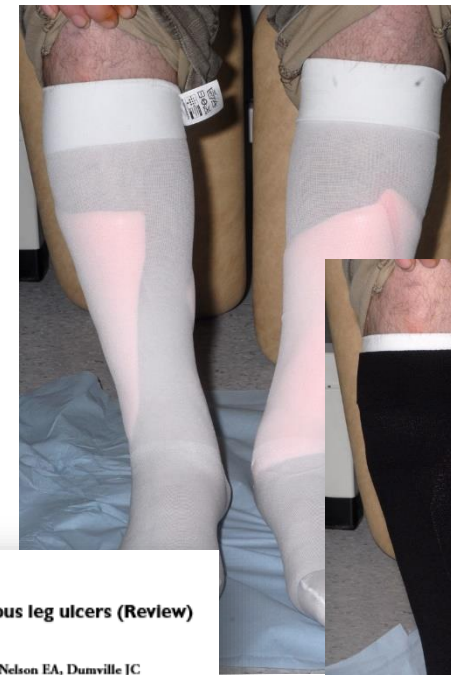Power of Compression



Presentation 27/7/09


Review 13/8/09

Healed 15/9/09

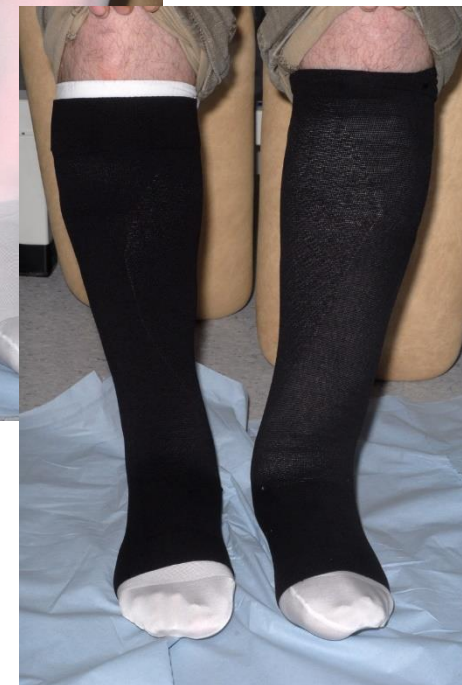

Compression for venous leg ulcers (Review)

O'Meara S, Cullum N, Nelson EA, Dumville JC



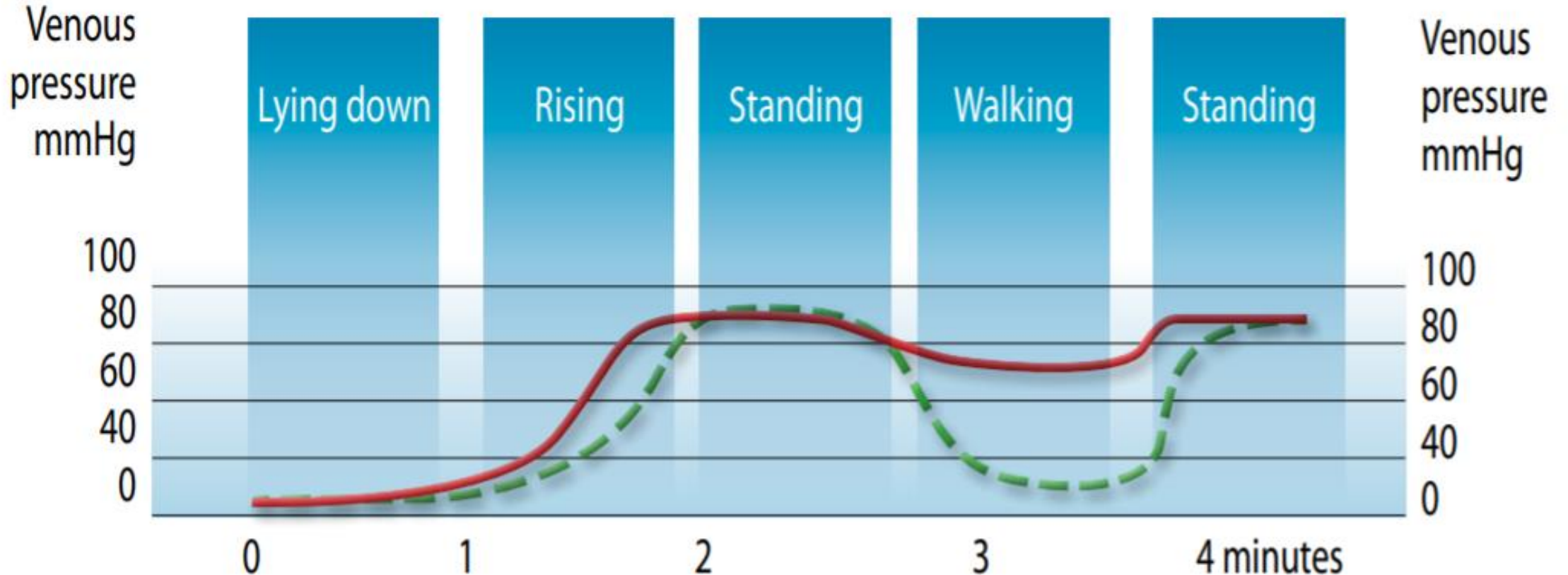
THE COCHRANE
COLLABORATION®



Society of Vascular Nurses

SVN
www.svn.org.uk

Venous pressure



https://lohmann-rauscher.co.uk/downloads/clinical-evidence/Effective_compressio.pdf

Diagnosis

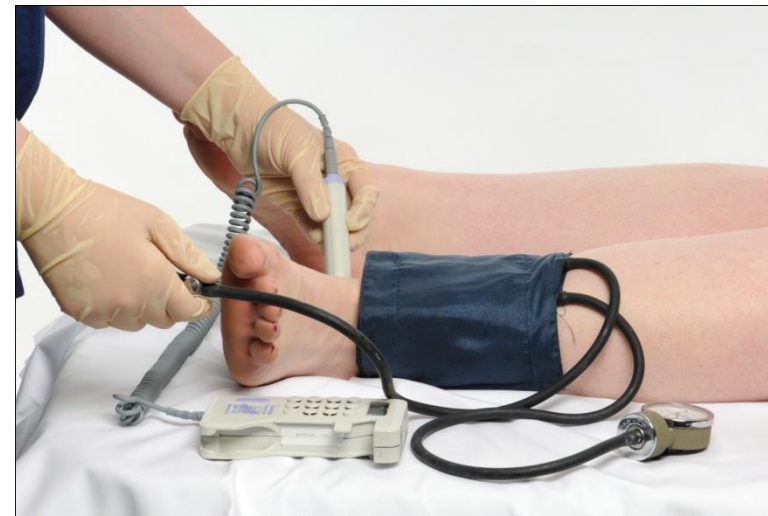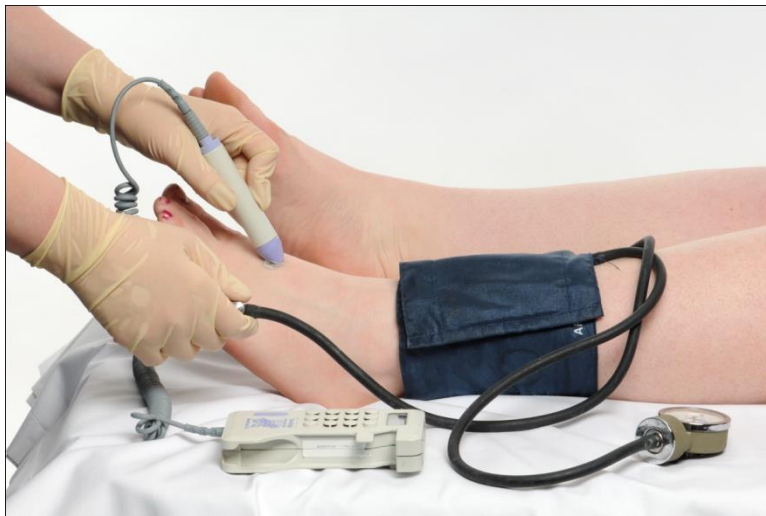- How do you diagnosis the aetiology of a leg ulcer?
- Detailed history
- Vascular risk factors
- Physical examination
- Limb examination
- Ulcer history
- Physical assessment — *remember, ABPI assessment can only confirm or deny the presence of arterial disease, NOT diagnose venous ulceration*

Doppler assessment

ABPI = ankle brachial pressure index

Simple vascular assessment using a doppler device

Determines the ratio of the ankle to the brachial systolic pressure



Doppler assessment

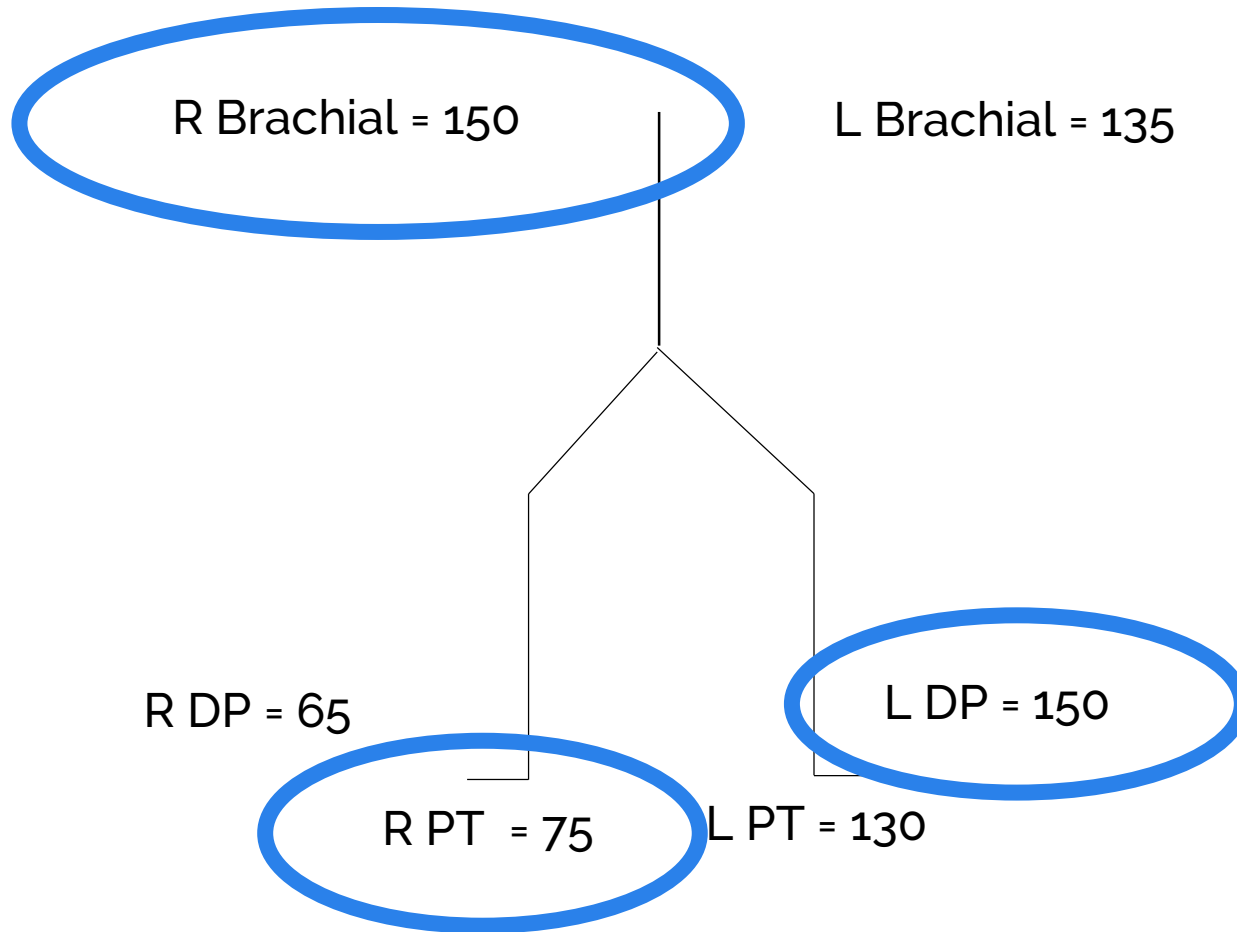
ABPI should not be conducted when:

- Patient has suspected deep vein thrombosis (if patient has confirmed DVT and on anticoagulation therapy ABPI can be undertaken)
- Patient is in sitting position (as results are unreliable)

Caution is required if:

- Patient has possible cellulitis, as procedure may be too painful
- Skin around gaiter fragile, as can result in further skin damage

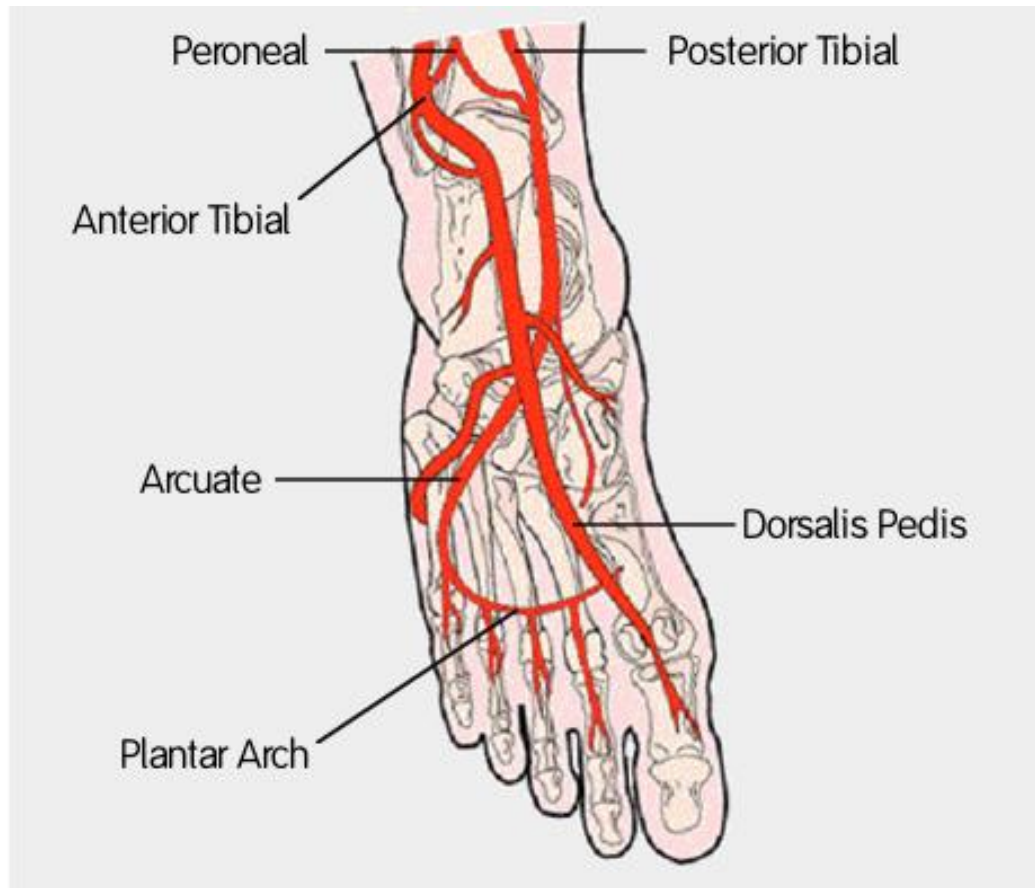
ABPI



L ABPI $150/150 = 1$

R ABPI $75/150 = 0.5$

ABPI results



- **0.8–1.3 — Normal**
- **0.6–0.8 — Mixed disease**
- **<0.6 — Arterial disease**
- **>1.3 — Caution, vessels may be calcified**

Trust when low but not high

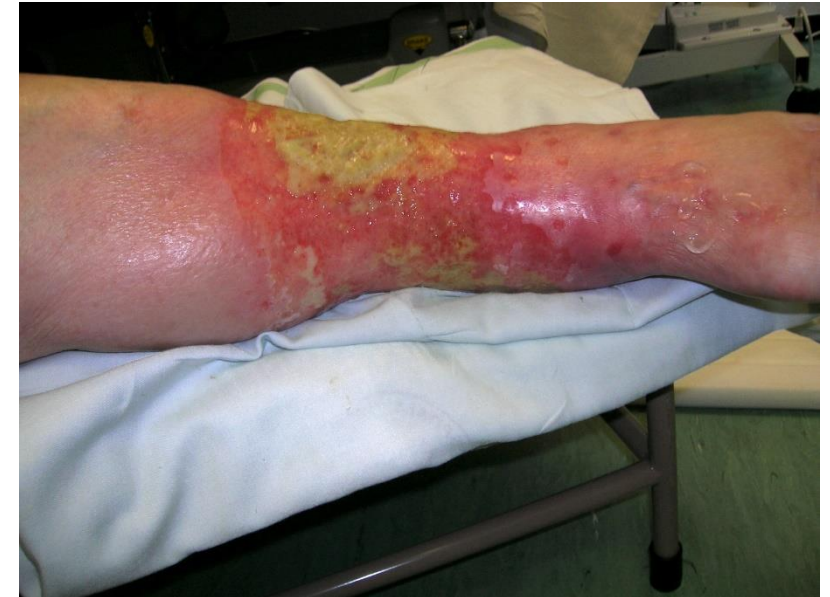Treatment for mixed ulceration

Involving which elements?

- Venous
- Lymphatic
- Arterial

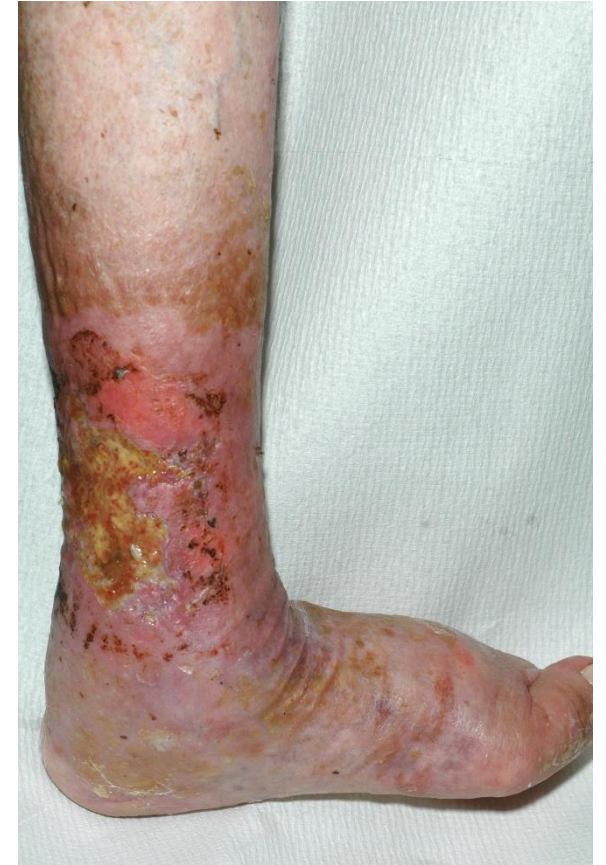Establish predominate element:

- Venous: compression therapy
- Lymphatic: compression therapy
- Arterial: explore revascularisation



Compression in mixed disease

- ABPI 0.5–0.79 — reduced compression
- Caution pressure damage rather than arterial flow restriction
- Check sensation
- Protect vulnerable areas



Compression in arterial disease

Compression therapy in mixed ulcers increases venous output and arterial perfusion

Giovanni Mosti, MD,^a Maria Letizia Iabichella, MD,^a and Hugo Partsch, MD,^b *Lucca, Italy; and Vienna, Austria*

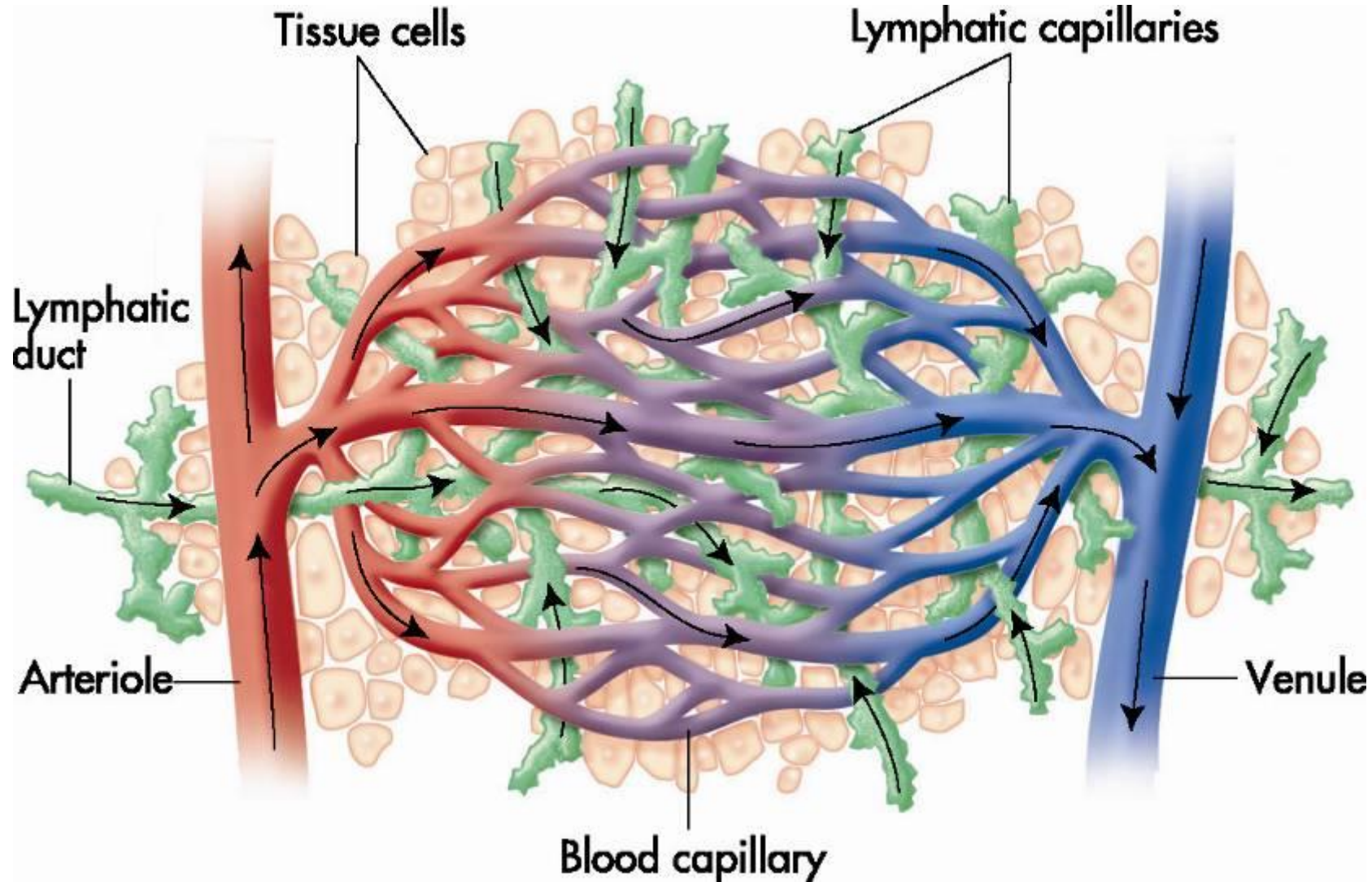
Objectives: This study was conducted to define bandage pressures that are safe and effective in treating leg ulcers of mixed arterial-venous etiology.

Methods: In 25 patients with mixed-etiology leg ulcers who received inelastic bandages applied with pressures from 20 to 30, 31 to 40, and 41 to 50 mm Hg, the following measurements were performed before and after bandage application to ensure patient safety throughout the investigation: laser Doppler fluxmetry (LDF) close to the ulcer under the bandage and at the great toe, transcutaneous oxygen pressure (TcPO₂) on the dorsum of the foot, and toe pressure. Ejection fraction (EF) of the venous pump was performed to assess efficacy on venous hemodynamics.

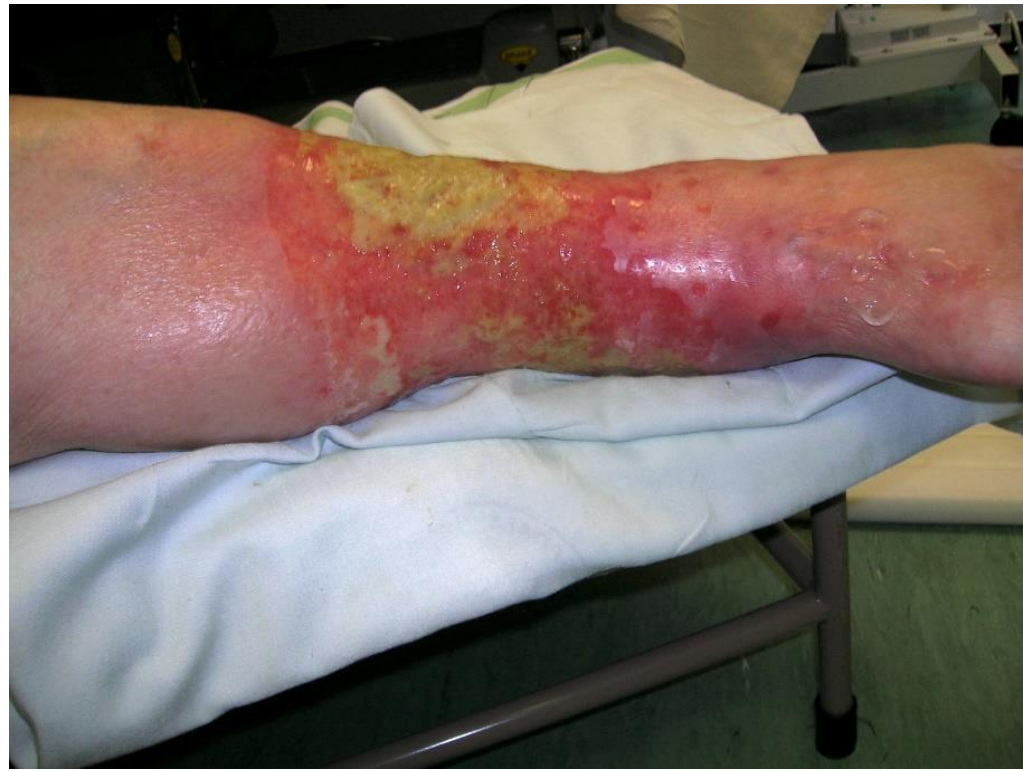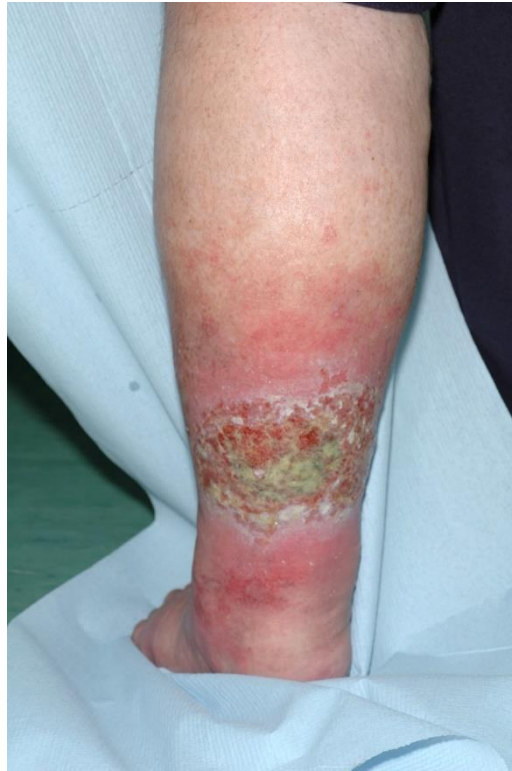Results: LDF values under the bandages increased by 33% (95% confidence interval [CI], 17-48; $P < .01$), 28% (95% CI, 12-45; $P < .05$), and 10% (95% CI, -7 to 28), respectively, under the three pressure ranges applied. At toe level, a significant decrease in flux of -20% (95% CI, -48 to 9; $P < .05$) was seen when bandage pressure >41 mm Hg. Toe pressure values and TcPO₂ showed a moderate increase, excluding a restriction to arterial perfusion induced by the bandages. Inelastic bandages were highly efficient in improving venous pumping function, increasing the reduced ejection fraction by 72% (95% CI, 50%-95%; $P < .001$) under pressure of 21 to 30 mm Hg and by 103% (95% CI, 70%-128%; $P < .001$) at 31 to 40 mm Hg.

Conclusions: In patients with mixed ulceration, an ankle-brachial pressure index >0.5 and an absolute ankle pressure of >60 mm Hg, inelastic compression of up to 40 mm Hg does not impede arterial perfusion but may lead to a normalization of the highly reduced venous pumping function. Such bandages are therefore recommended in combination with walking exercises as the basic conservative management for patients with mixed leg ulcers. (J Vasc Surg 2012; 55:122-8.)

Relationship of the lymphatic system



Oedema compression

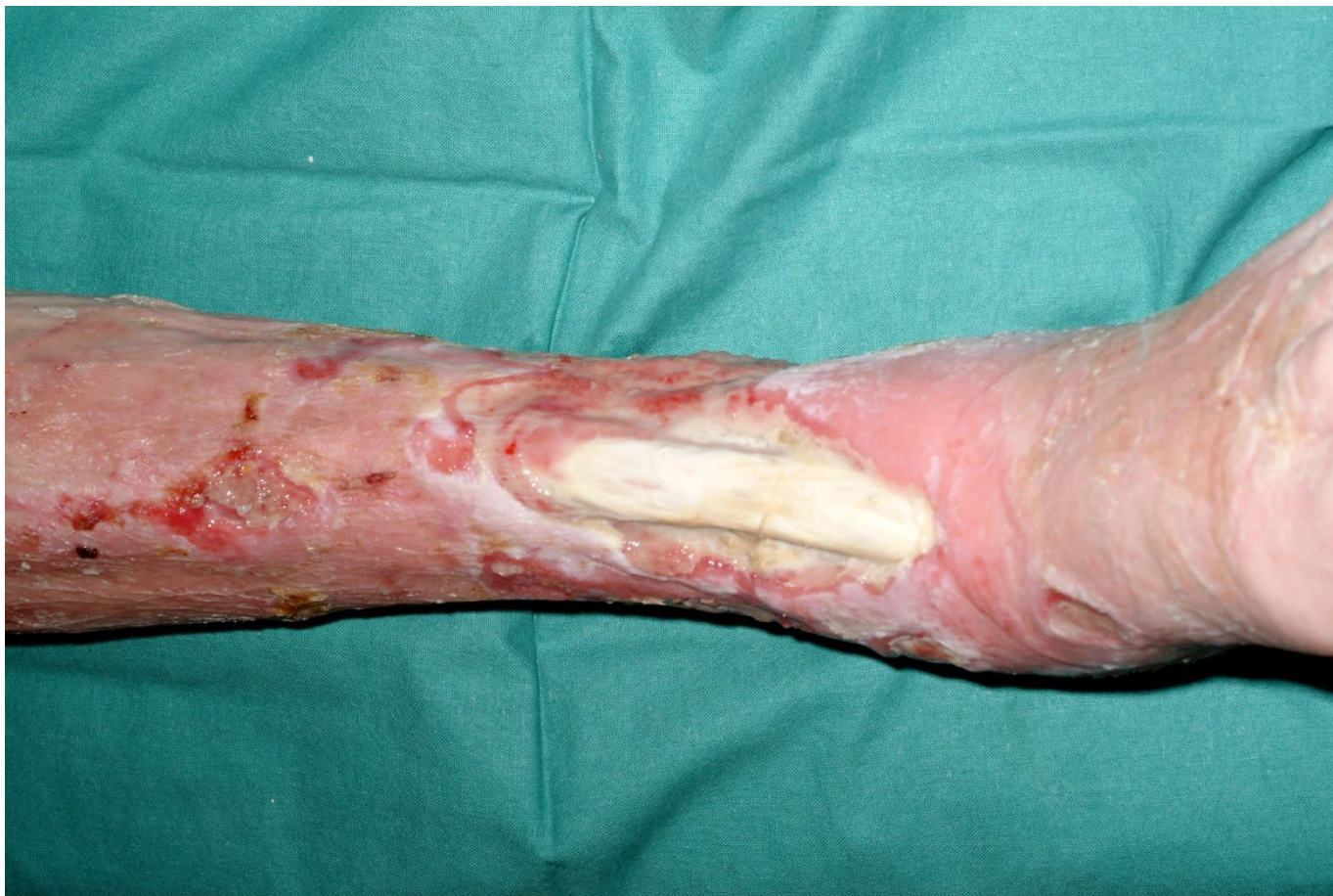

Benefits of compression

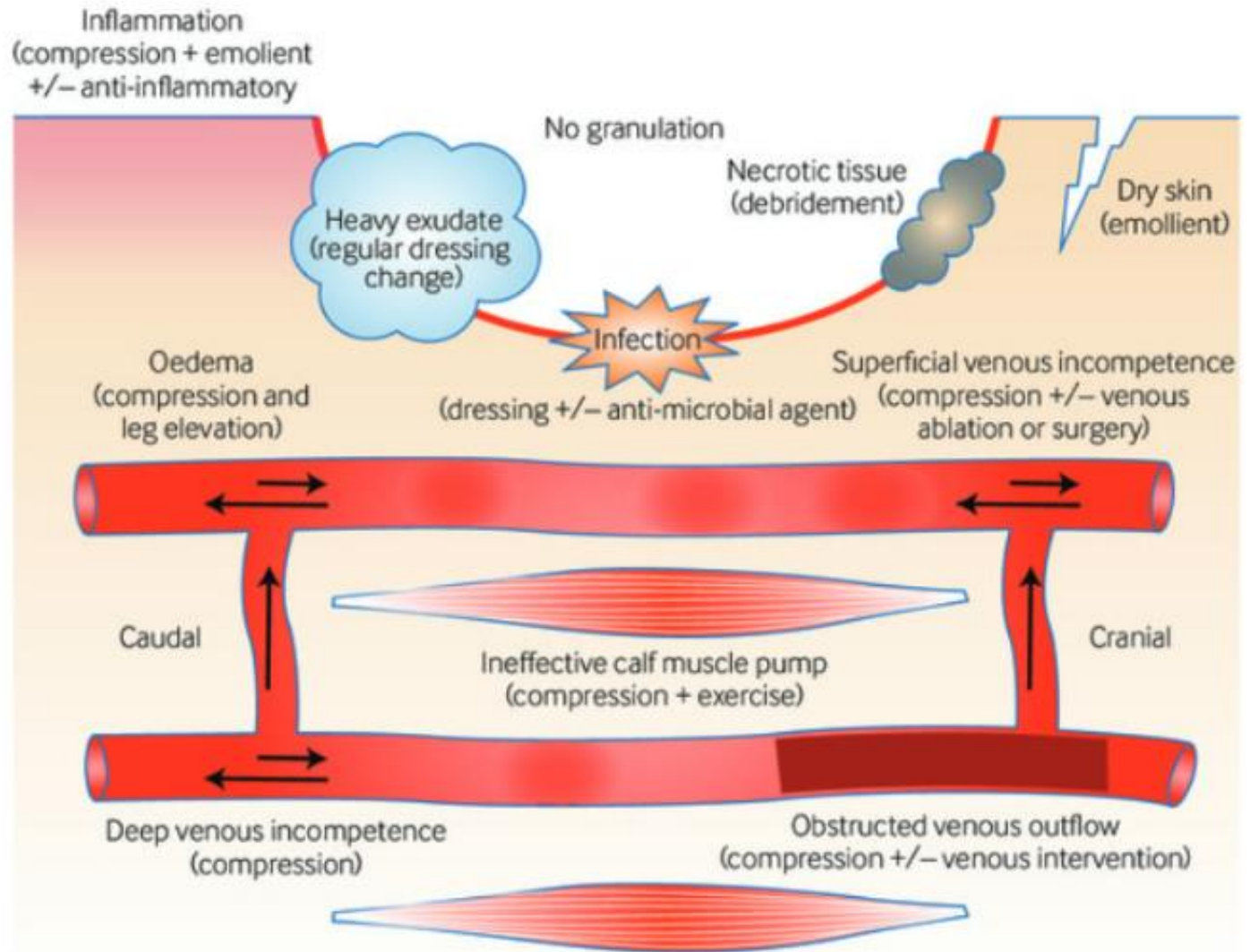
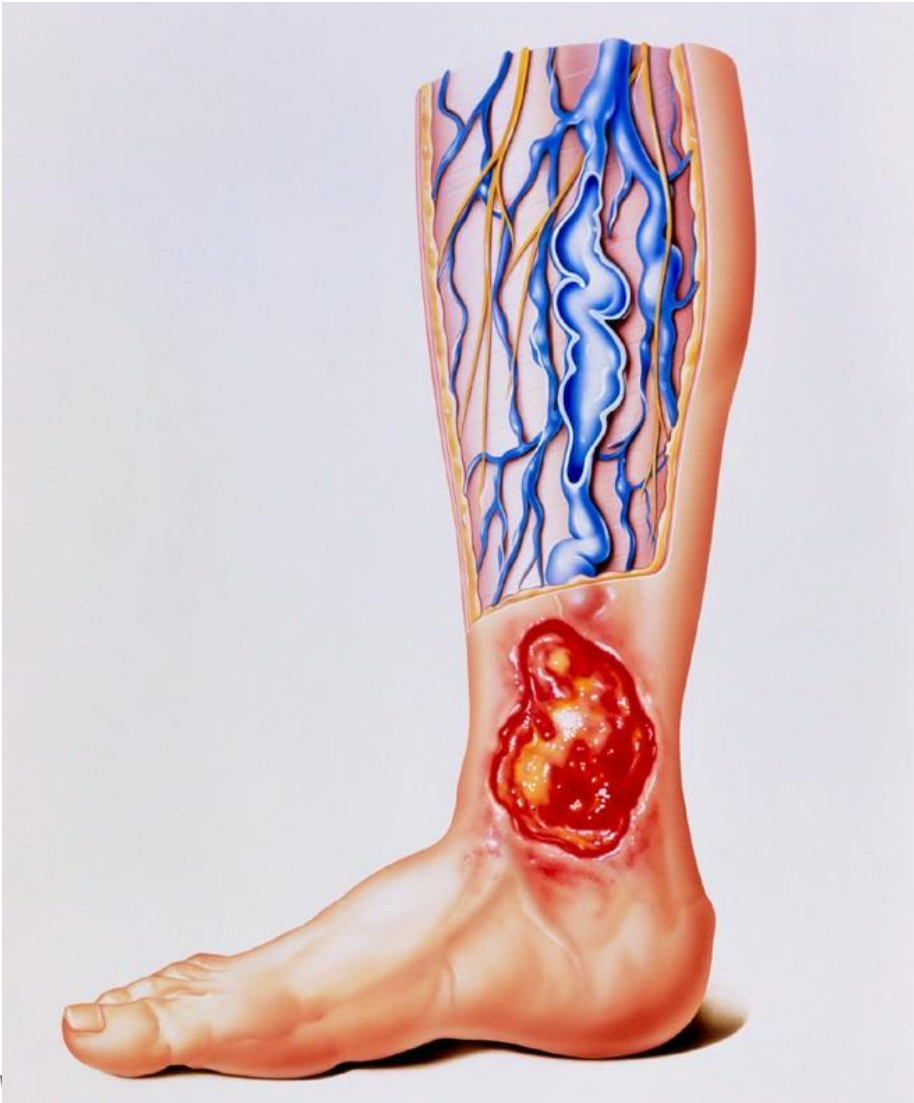- Venous incompetence and oedema will reduce arterial flow
- Venous hypertension reduces the intravascular pressure gradient — reducing perfusion pressure
- Oedema pushes blood capillaries apart — increasing distance between blood capillary and cells — impeding nutrient transportation

Compression therapy improves all of the above

Bandage damage



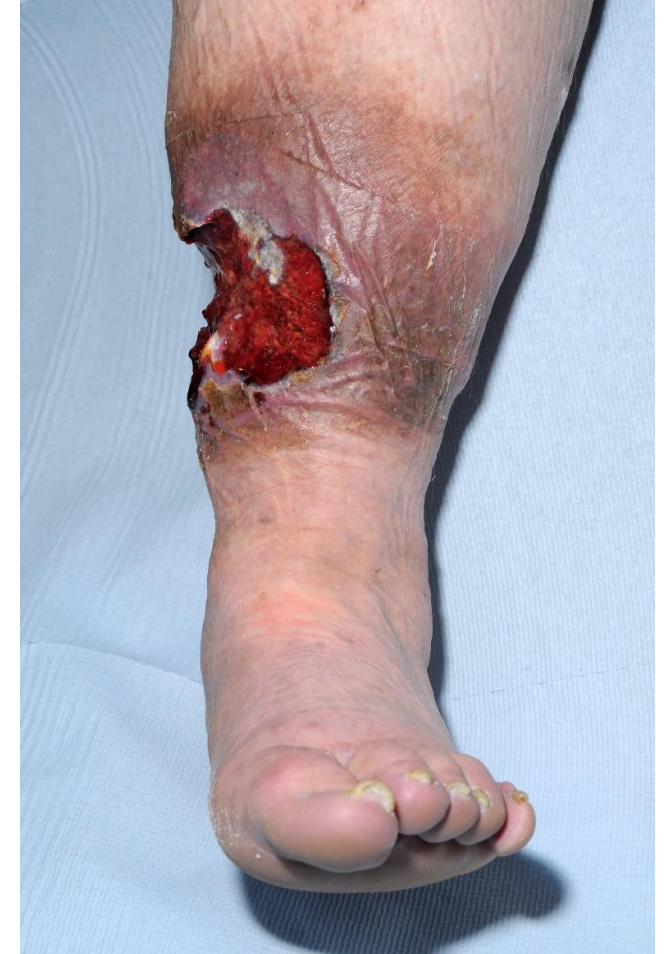Leg ulcer - 'a weed'



Lack of confidence = harm

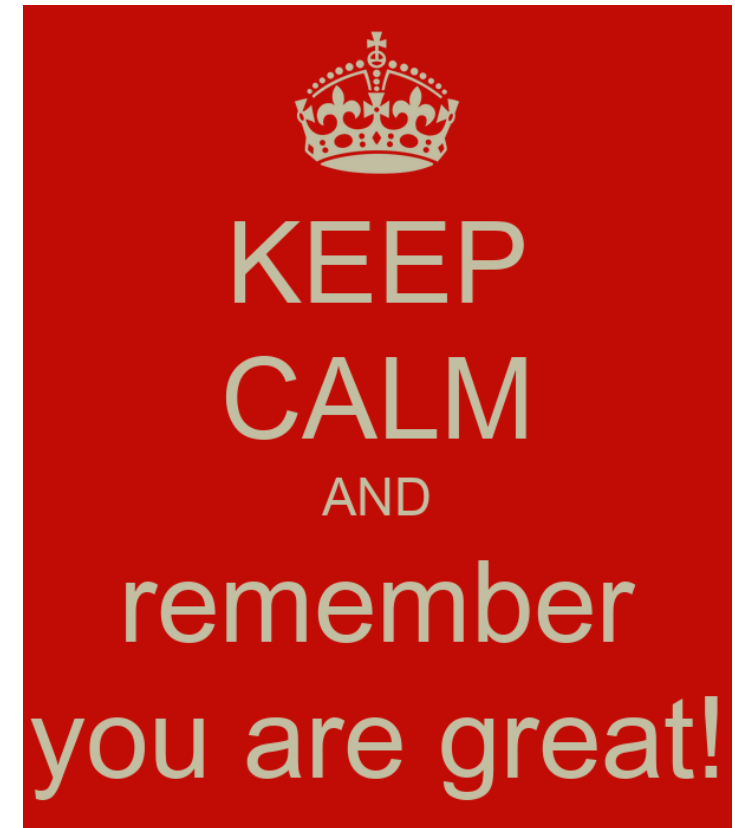- 420,000 leg ulcers without diagnosis
- The older the ulcer, the harder to heal
- 47% healing at six months
- 10% chance of healing from 6–12 months

We are causing harm if delaying assessment/compression



Your confidence level

- Greater understanding of venous, arterial and lymphatic systems
- Increased knowledge of treatment options
- Improved understanding of compression therapy
- Increasing confidence
- Improving decision making
- Changing patients' lives





Download your certificate



www.wct-live.co.uk/certificate